



UNIVERSIDADE DE LISBOA
Faculdade de Medicina Veterinária

COMPLICATIONS ASSOCIATED WITH CLOSING WEDGE OSTECTOMY
PROCEDURE FOR TREATMENT OF CRANIAL CRUCIATE LIGAMENT RUPTURE IN
DOGS: A RETROSPECTIVE STUDY OF 145 CASES

MARIANA MELO BORGES

CONSTITUIÇÃO DO JÚRI

Doutor António José de Almeida Ferreira

Doutor Luís Miguel Alves Carreira

Doutora Lisa Alexandra Pereira Mestrinho

ORIENTADOR

Dr. David Robinson

CO-ORIENTADORA

Doutora Lisa Mestrinho

2016
LISBOA



UNIVERSIDADE DE LISBOA
Faculdade de Medicina Veterinária

COMPLICATIONS ASSOCIATED WITH CLOSING WEDGE OSTECTOMY
PROCEDURE FOR TREATMENT OF CRANIAL CRUCIATE LIGAMENT RUPTURE IN
DOGS: A RETROSPECTIVE STUDY OF 145 CASES

MARIANA MELO BORGES

DISSERTAÇÃO DE MESTRADO INTEGRADO EM MEDICINA VETERINÁRIA

CONSTITUIÇÃO DO JÚRI

Doutor António José de Almeida Ferreira

Doutor Luís Miguel Alves Carreira

Doutora Lisa Alexandra Pereira Mestrinho

ORIENTADOR

Dr. David Robinson

CO-ORIENTADORA

Doutora Lisa Mestrinho

2016
LISBOA

To my family...

Acknowledgements

First, I would like to thank David Robinson, my supervisor, without whom this dissertation would not have been possible, that, along with the other clinical directors of KVG, welcomed me to their hospital, allowing me to be part of the team and have such an important experience as a trainee. His enthusiasm and dedication towards the profession inspired me and I would like to recognize all his support and mentorship during this period.

Thanks to Hugo Martins, the best partner one could long for, for supporting, motivating and inspiring me every day. For triggering this great opportunity of working with KVG. For being a mentor and an example to follow. I could not be more grateful for sharing a life with you.

Thanks to all my dear colleagues from Lisbon Veterinary Medicine Faculty, who I lived this incredible journey with, those who guided and supported me, whom I shared laughter and tears with and always reminded me I was not alone throughout these tough 6 years. I will not forget all our mutual worries and fears, all the adventures we lived together and the hard work we had. I cannot imagine going through everything without you. Next, I would like to thank my best friends, with a special reference to Mariana Castro, Catarina Mendonça and Maria Guiomar, whom I grew up with and who always supported me through the years. Thank you so much for your valuable friendship. I am certain that countless adventures await us in the future.

I would also like to thank Dr. Lisa Mestrinho, my co-supervisor, for her availability and support. I will always recognize the extraordinary Professor she is, inspiring me throughout my time in faculty.

I could not be more thankful to all KVG team for acknowledging me and giving me the opportunity to practice in different departments of veterinary medicine. Thanks to all the Vets for spending a lot of their precious time teaching me and answering my questions. A special thanks to Natasha Hillary and Nuno Neves for teaching and allowing me to “steal” many of their routine surgeries, and also for letting me assist them in other procedures. A massive thanks to Joana Miranda for being such a good friend and for sharing her knowledge with me. Thanks a lot to Richard Jones for his patience and sense of humour while teaching me his consulting strategies. To all the nurses, I cannot thank you enough for all your support and professionalism. Thanks to Louise Jackson for her availability and effort making sure everyone was happy at work.

At last and most important, I want to thank my whole family, with special reference to my parents for all the hard work they put into my education, teaching me about life and always fighting for my happiness. I hope I can be half as wonderful as you are. You have always supported and loved me, even when I was not very lovable. A special thanks to my fabulous sister for always standing up for me and holding my hand. Growing up with you was a blessing. The things I learned from you are countless and I could not be more grateful. Without you three I could not be the person I am now, and therefore, this work could not have been possible. I am proud of you and hope to make you proud of me.

Abstract

COMPLICATIONS ASSOCIATED WITH CLOSING WEDGE OSTECTOMY PROCEDURE FOR TREATMENT OF CRANIAL CRUCIATE LIGAMENTE RUPTURE IN DOGS: A RETROSPECTIVE STUDY OF 145 CASES

Cranial cruciate ligament (CrCL) rupture is one of the most common causes of lameness in dogs and the leading cause of osteoarthritis in this species, therefore, expressing a relevant clinical and economic impact in veterinary medicine. Despite the great variety of surgical techniques available for management of this condition, the perfect treatment is yet to be found. Currently, the tibial osteotomies are preferred over the intracapsular and extracapsular techniques. The cranial closing wedge ostectomy procedure (CWO) for the tibial plateau levelling has been used for several years to provide dynamic stabilization of the stifle joint in cases of CrCL failure. In this technique, a wedge of bone is removed from the proximal tibia, aiming to reduce the tibial plateau angle (TPA) and, consequently, neutralise the cranial tibial thrust, so that the need for a CrCL is eliminated. Nevertheless, alike all the other surgical procedures, intraoperative and postoperative complications are sometimes observed following CWO surgery. In this retrospective study, complications resulting from a series of 145 cases of CWOs were evaluated. All procedures were performed by only one surgeon at Kingston Veterinary Group, in Hull, with a minimum of 6 months follow-up period. The overall complication rate was 18.6% (27/145) and the rate of complications requiring further surgical intervention, defined as major complications, was 3.4% (5/145), and included subsequent meniscal injury, implant failure and infection. Minor complications, defined as those not requiring second surgery, occurred in 15.2% (22/145) of the cases, with surgical wound infection being the most common complication encountered. The rate of major complications obtained in the present study is comparable to the ones most recently reported for TPLO procedure. In conclusion, a reasonably low rate of complications can be expected following CWO procedure when performed by experienced surgeons of the surgical technique.

Keywords: Cranial cruciate ligament, closing wedge ostectomy, complications, tibial plateau levelling, surgery

Resumo

COMPLICAÇÕES ASSOCIADAS COM A CLOSING WEDGE OSTECTOMY PROCEDURE PARA O TRATAMENTO DA RUPTURA DO LIGAMENTO CRUZADO CRANIAL EM CÃES: UM ESTUDO RETROSPECTIVO DE 145 CASOS

A rutura do ligamento cruzado cranial é uma das causas mais comuns de claudicação em cães, sendo a principal causa de osteoartrite nesta espécie, mostrando um relevante impacto clínico e económico em medicina veterinária. Apesar da grande variedade de técnicas cirúrgicas disponíveis para o tratamento desta doença não existe, até ao momento, uma técnica cirúrgica mais eficiente. No entanto, as osteotomias tibiais parecem ser preferidas em relação às técnicas intracapsulares e extracapsulares. A cirurgia *closing wedge ostectomy* para nivelamento do *plateau* tibial tem vindo a ser utilizada desde há muitos anos para promover estabilização dinâmica da articulação do joelho, em casos de insuficiência do ligamento cruzado cranial. Nesta técnica, um fragmento de osso em cunha é removido da parte proximal da tibia, com o objetivo de reduzir o ângulo do *plateau* tibial e, conseqüentemente, neutralizar o movimento cranial da tibia durante compressão (*cranial tibial thrust*), de forma a não ser necessária a existência de um ligamento cruzado cranial. No entanto, bem como todas as outras cirurgias, complicações intraoperatórias e pós-operatórias são, também, observadas nesta técnica. Neste estudo retrospectivo em 145 casos, descreve-se o procedimento cirúrgico procedendo-se ao registo e análise das complicações em um período mínimo de 6 meses pós-cirúrgico. A taxa geral de complicações foi de 18.6% (27/145) e a taxa de complicações que necessitaram uma segunda intervenção cirúrgica, designadas de complicações maiores, foi de 3.4% (5/145), sendo a lesão subsequente do menisco, a falha do implante e a infeção. As complicações menores, definidas como aquelas que não necessitaram segunda intervenção cirúrgica, ocorreram em 15.2% (22/145) dos casos, sendo a infeção da ferida cirúrgica a mais frequente. A taxa de complicações maiores obtida no presente estudo é comparável a estudos anteriores para outras técnicas cirúrgicas. É possível concluir que uma taxa significativamente baixa de complicações pode ser esperada nesta técnica quando realizada por cirurgiões com experiência na mesma.

Palavras-chaves: Ligamento cruzado cranial, *closing wedge ostectomy*, complicações, nivelamento do *plateau* tibial, cirurgia

TABLE OF CONTENTS

INTERNSHIP REPORT	1
I. INTRODUCTION.....	3
1. ANATOMY AND BIOMECHANICS OF THE STIFLE JOINT	3
1.1. Stifle anatomy	3
1.2. Cranial cruciate ligament	6
1.2.1. General macroanatomy.....	6
1.2.2. General microanatomy and neurovascular supply	7
1.2.3. Functional anatomy	8
1.3. Biomechanics of the intact stifle.....	8
2. CRANIAL CRUCIATE LIGAMENT DISEASE	11
2.1. Pathogenesis	11
2.2. Biomechanics of the CrCL-deficient stifle	13
2.3. Meniscal tears	14
2.4. Epidemiology	15
2.5. Clinical history.....	16
2.6. Clinical signs	17
2.7. Diagnostic imaging	19
2.7.1. Radiography.....	19
2.7.2. Ultrasonography	21
2.7.3. Computed tomography	22
2.7.4. Magnetic Resonance Imaging.....	22
2.7.5. Arthroscopy.....	23
3. TREATMENT OF CRANIAL CRUCIATE LIGAMENT RUPTURE.....	24
3.1. Conservative management	24
3.2. Surgical management.....	25
3.2.1. Intra-articular or intracapsular techniques.....	26
3.2.3. Tibial Plateau Levelling Techniques.....	28
3.2.3.1. Closing Wedge Osteotomy	29
3.2.3.2. Tibial Plateau Levelling Osteotomy	32
3.2.4. Tibial Tuberosity Advancement.....	34
4. OVERVIEW OF COMPLICATIONS ASSOCIATED WITH SURGICAL MANAGEMENT OF THE CRANIAL CRUCIATE LIGAMENT RUPTURE.....	36
4.1. Degenerative joint disease	36

4.2. Infection.....	37
4.3. Delayed bone healing	39
4.4. Subsequent meniscal disease	39
4.5. Osteosarcoma.....	40
4.6. Implant failure.....	41
4.7. Bone fractures.....	41
5. OBJECTIVES	42
II. MATERIALS AND METHODS	43
1. Inclusion criteria	43
2. Signalment	43
3. Radiographic assessment	43
4. Procedures	44
4.1. Measurement of the TPA.....	44
4.2. Preoperative management.....	45
4.3. Surgical Technique.....	46
4.4. Postoperative management.....	49
5. Complications.....	50
III. RESULTS	51
1. Signalment	51
2. Radiographic and Surgical findings.....	51
3. Radiographic re-evaluation and follow-up.....	52
4. Complications.....	52
4.1. Major complications	52
4.2. Minor complications	54
IV. DISCUSSION	57
V. CONCLUSION.....	68
REFERENCES	70

LIST OF FIGURES

Figure 1: Ligaments and menisci of the stifle joint.....	4
Figure 2: Dorsal view of the menisci and ligaments of the left stifle joint	6
Figure 3: Drawing illustrating the degrees of freedom of the femorotibial articulation	9
Figure 4: Mechanics of the CrCL-deficient stifle.....	14
Figure 5: Radiographs of a normal stifle and one with CrCL rupture.	20
Figure 6: Illustrations of lateral femorotibial suture and TightRope techniques.....	27
Figure 7: Illustrations of the Closing Wedge Osteotomy Procedure	29
Figure 8: Illustrations of Tibial Plateau Levelling Osteotomy Procedure.....	32
Figure 9: Illustrations of the Tibial Plateau levelling osteotomy	35
Figure 10: Postoperative radiographs.....	44
Figure 11: Tibial Plateau Measurement on a lateral view radiograph.....	45
Figure 12: Positioning, draping and preparation for the surgical procedure.....	46
Figure 13: First steps of CWO procedure.....	47
Figure 14: Some steps of CWO procedure.....	48

LIST OF TABLES

Table 1: Major complications (defined as subsequent surgical intervention) following Tibial Plateau Levelling by Closing Wedge Osteotomy in 145 stifle joints in 108 dogs	54
Table 2: Minor complications (defined as no further surgical intervention) following Tibial Plateau Levelling by Closing Wedge Osteotomy in 145 stifle joints in 108 dogs	56

LIST OF ABBREVIATIONS AND SYMBOLS

- ® - Registered Trademark
- ° – Degree
- AO – Osteoarthritis
- CaCL – Caudal cruciate ligament
- CrCL – Cranial cruciate ligament
- CT – Computed tomography
- CTA – Computed tomography arthrography
- CWO – Closing wedge ostectomy
- DJD – Degenerative joint disease
- IM – Intramuscular
- IMS – Industrial methylated spirit
- IV – Intravenous
- Kg – Kilogram
- KVG – Kingston Veterinary Group
- mg/kg – Milligrams per kilogram
- mm – Millimeters
- MRI – Magnetic resonance imaging
- MRSA – *Methicillin-resistant staphylococcus aureus*
- NSAID – Nonsteroidal anti-inflammatory drug
- PTA – Patella tibial angle
- SC – Subcutaneous
- TPA – Tibial plateau angle
- TPLO – Tibial plateau levelling osteotomy
- TTA – Tibial tuberosity advancement
- UK – United Kingdom
- USA – United States of America
- v/v – Volume per volume
- w/v – Weight per volume
- µg/kg/min – Micrograms per kilogram per minute
- CRI – Constant rate infusion

INTERNSHIP REPORT

As part of the Integrated Masters Degree in Veterinary Medicine from the Faculty of Veterinary Medicine, University of Lisbon, I completed a 6-month training at Kingston Veterinary Group, Hull, UK, between 2nd September 2015 and 27th February 2016, in a total of approximately 1100 hours. During that time I assisted and participated in several procedures carried out in different areas of small animal practice. In the Surgery department, headed by Dr. David Robinson, I collaborated helping in several orthopaedic procedures (e.g. CWO, Fabello-tibial Suture, Tibial Tuberosity Transposition, Fracture repairs, Transcarpal and Transtarsal arthrodesis, placement of transcondylar screw for correction of IOHC), soft tissue surgeries (e.g. splenectomies, exploratory laparotomies, cystotomies, brachycephalic airway syndrome surgery, laparoscopies) and postoperative care of the patients. I was also able to develop my surgical skills by performing various surgical procedures under supervision of senior surgeons, such as dog, cat and rabbit castrations, dog and cat ovariohysterectomies, umbilical hernia repair, dewclaw removal, pyometra, and dentistry procedures such as teeth extraction, scaling and polishing. In terms of Anaesthesia, I was able to practice procedures such as induction, intubation and general anaesthetic monitoring. In the Internal Medicine department, I developed my clinical case solving skills and participated in the care and treatment of the inpatients, practicing procedures such as drugs administration, blood sampling, catheterization, cystocentesis and running several diagnostic tests. In the Diagnostic Imaging department, I assisted the surgeons during endoscopy and ultrasound scans and was able to practice patient positioning during radiographic examination. During and after these procedures, I was taught by the senior vets to interpret the results and take conclusions towards diagnostic and treatment planning in specific clinical cases.

During the period - December 2015 to May 2016 - and with the prized support of my supervisor David Robinson, who kindly provided all his clinical records for the research subject that lead to this dissertation paper.

I. INTRODUCTION

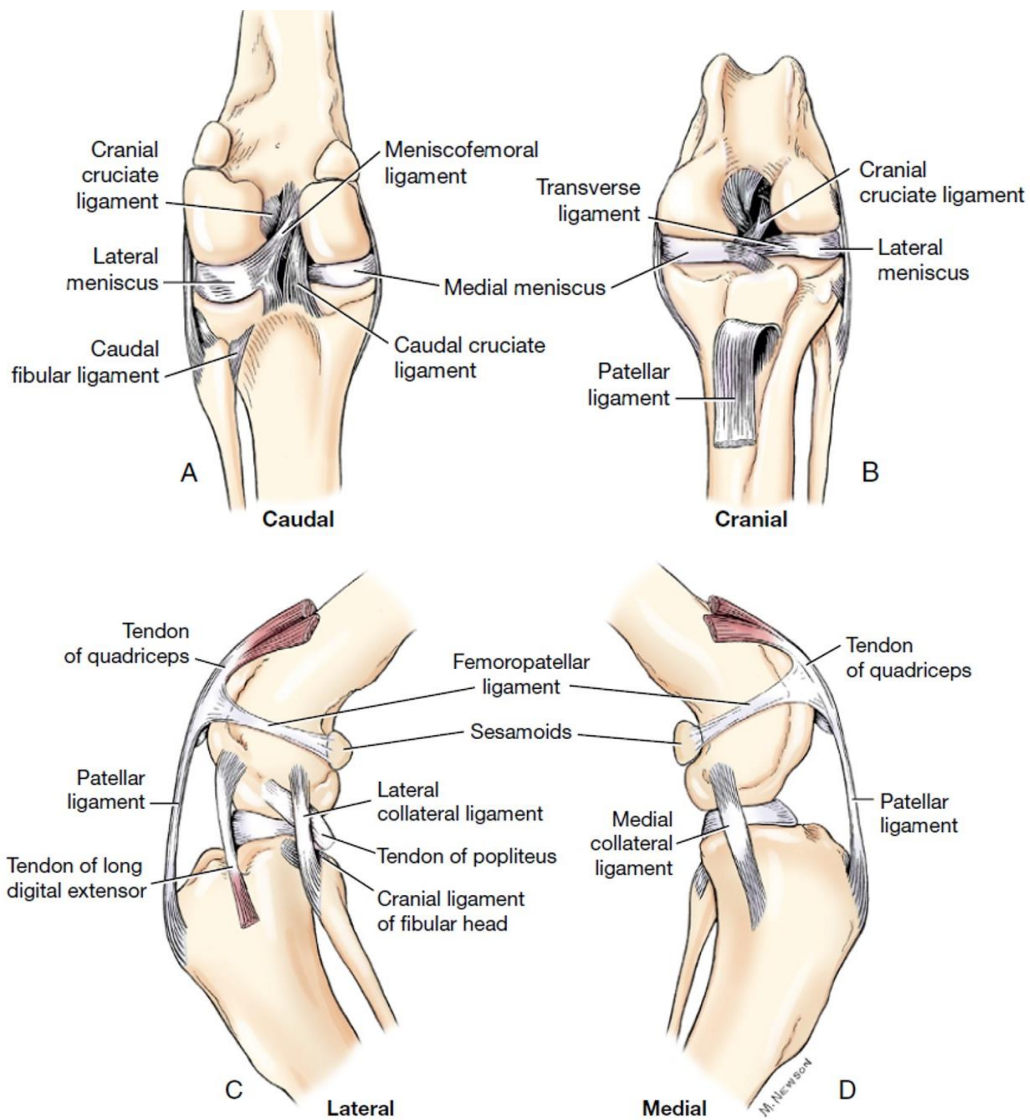
Cranial cruciate ligament (CrCL) disease is one of the most common orthopaedic conditions seen in dogs (Corr, 2009; Hayashi, Manley & Muir, 2004) and the leading cause of osteoarthritis (OA) in this species (Hegemann, Wondimu, Kohn, Brunnberg & Schmidt, 2005). Therefore, is of great clinical and economic relevance in small animal practice. In 2003, owners spent \$1.32 billion for the treatment of CrCL disease in the United States (Wilke, Robinson, Evan, Rothschild & Conzemius, 2005). Several surgical techniques have been developed to manage this condition, attempting to alleviate pain, decrease stifle instability and minimise OA. Yet, there is not a single one that is considered entirely satisfactory (Vasseur, 2003), therefore, many practitioners are faced with a dilemma: choose the best technique for each case. Clinical research focusing on the outcome and complications associated with each surgical procedure has been published but yet with rather variable results.

1. ANATOMY AND BIOMECHANICS OF THE STIFLE JOINT

1.1. Stifle anatomy

The stifle joint is composed of three long bones - femur, proximal tibia and proximal fibula, and four sesamoid bones - the patella, lateral, medial and popliteal sesamoids, or fabellae (Robins, 1990; Evans & Hermanson, 1993). It is considered a compound joint because it comprises femorotibial, femoropatellar and proximal tibiofibular joints as well as the joints between the femur and paired sesamoids in the origins of the gastrocnemius and that between the tibia and the sesamoid in the popliteus tendon, all sharing a common synovial cavity (Robins, 1990). The articular ends of the main three bones that compose the stifle are covered by the articular cartilage, which is a smooth, compressible and avascular structure that reduces friction and concussion. The joint capsule, with an outer dense fibrous layer, which attaches to the periosteum, and an inner synovial membrane that is highly vascularized and produces the synovial fluid, surrounds the stifle. The capsule also contains the nerve supply and produces phagocytic synoviocytes (Leeson, Leesson & Paparo, 1988). The synovial fluid is colourless, viscous and primarily composed of water and a strongly polymerised hyaluronic acid (Lesson et al., 1988, Evans & Hermanson, 1993). It provides lubrication, supplies the joint with nutrients and removes waste from the hyaline articular cartilage (Leeson et al., 1988; Evans & Hermanson, 1993).

Figure 1: Ligaments and menisci of the stifle joint. (A) Ligaments and menisci of the left stifle joint, caudal view. (B) Ligaments and menisci of the left stifle joint, cranial view. (C) Ligaments and menisci of the left stifle joint, lateral view. (D) Ligaments and menisci of the left stifle joint, medial view. (From: Evans, H. E. & de Lahunta, E. *Arthrology. Guide to the Dissection of the Dog*, 7th ed., 2010, p. 72. Saunders Elsevier.)



The bones of the stifle joint contain processes for the origin and insertion of muscles and ligaments; therefore, playing a major role in the mechanics of stifle joint motion (Robins, 1990; Evans & Hermanson, 1993). The ligaments are strong bands of fibrous connective tissue connecting the bones and these can be intracapsular when located within the capsule like the cruciate ligaments or can be extracapsular when located outside or as part of the joint capsule like the collateral ligaments. There are 15 ligaments in the stifle joint. Four of them are the anatomical structures of major importance in providing stability of the joint. Two of them are the collateral ligaments: the medial and lateral collateral ligaments, which stabilize the medial

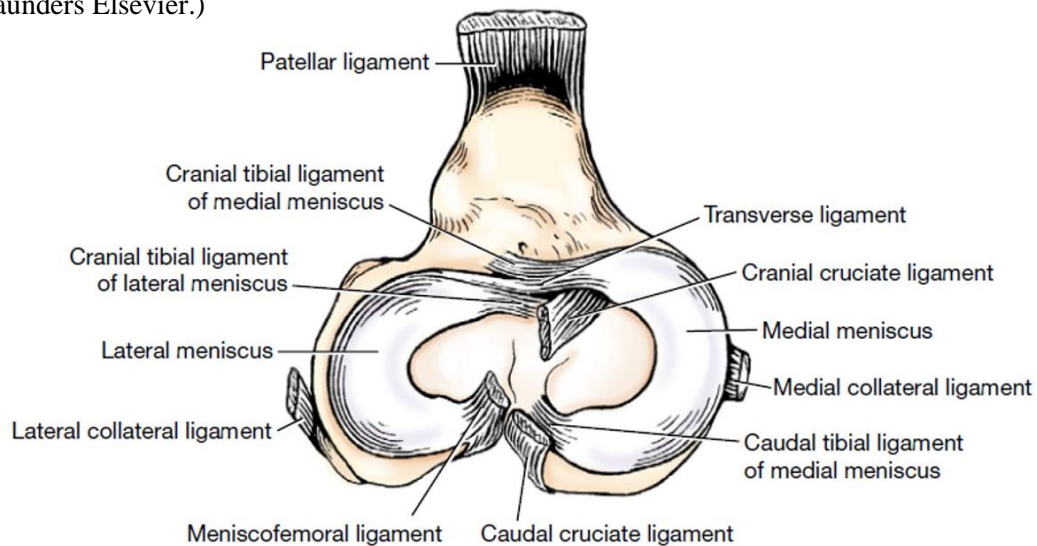
and lateral sides of the joint and the other two are called cruciate ligaments: the cranial and the caudal (Arnoczky, 1988). The lateral collateral ligament originates in the lateral femoral epicondyle and extends caudodistally to insert on the fibular head. During flexion the ligament is loose, allowing the lateral femoral condyle to freely move caudally resulting in internal rotation of the tibia, whereas in extension it is taut (Vasseur & Anorczyk, 1981). The medial collateral ligament originates on the medial femoral epicondyle and extends distally, forming an attachment with the joint capsule and the medial meniscus and inserts on the proximal medial tibia. Between the ligament and the tibia, a fluid-filled bursa can be identified, which reduces friction and helps the movement of the ligament caudally during flexion of the stifle (Vasseur & Arnoczky, 1981). The cranial and caudal cruciate ligaments are named for their tibial attachment. Therefore, the CrCL, which is the lateral one, arises from the caudolateral femur within the intercondylar fossa, running craniodistally to attach cranially on the tibia. Further emphasis will be given to the CrCL later on this dissertation. The caudal cruciate ligament (CaCL), the medial one, originates at the lateral aspect of the medial femoral condyle and runs caudodistally to the lateral edge of the popliteal notch of the tibia, and prevents caudal movement of the tibia relatively to the femur. The cruciate ligaments receive their blood supply from the synovial sheaths that surround them and their mid-sections have a poorer blood supply than the proximal and distal ends (Vasseur, 2003).

The femoropatellar joint is formed between the femoral trochlea and the articular surface of the patella and the ligaments that connect the femur to the patella are the medial and lateral femoropatellar ligaments which are often vestigial and run from the patella to the fabellae and merge with the femoral fascia, functioning weakly to hold the patella in the trochlea (Robins, 1990; Evans & Hermanson, 1993). Distally, the patella connects to the tibial tuberosity by a single patellar ligament, which represents the insertion tendon of the quadriceps femoris. There are also two ligaments assisting the articulation of the head of the fibula to the fibular articular facet of the tibia, one cranial and one caudal (Robins, 1990; Evan & Hermanson, 1993).

Between the femoral and tibial condyles two biconcave C-shaped fibrocartilaginous structures can be identified, which are the medial and the lateral menisci (Arnoczky, 1993). They are semilunar structures in plan and wedge-shaped in section with thicker peripheral borders, providing stability and lubrication of the joint, compensating the incongruity of the tibial and femoral articular surfaces and helping relieve concussion (Robins, 1990; Arnoczky, 1993). Water is the main component of these structures, followed by large amounts of collagen, proteoglycans and glycosaminoglycans (Stephan, McLaughlin & Griffith, 1998). The major blood supply to the menisci is through branches of the medial and lateral genicular arteries, which supply the joint capsule giving rise to vessels that penetrate 15-25% of the width of the

menisci, which is why the central part of the menisci is nourished by the synovial fluid (Arnoczky, 1993).

Figure 2: Dorsal view of the menisci and ligaments of the left stifle joint, proximal end of the tibia (From: Evans, H. E. & de Lahunta, E. *Arthrology. Guide to the Dissection of the Dog*, 7th ed., 2010, p. 74. Saunders Elsevier.)



The menisci are secured to the tibia by two ligaments (one cranial and one caudal) each and one that attaches the lateral meniscus to the femur called menisofemoral ligament (Robins, 1990; Evan & Hermanson, 1993). The cranial meniscotibial ligaments extend to the cranial intercondyloid area, whereas the caudal meniscotibial ligaments attach to the caudal intercondyloid area just cranial to the CaCL and to the popliteal notch caudolateral to the CaCL, the medial and lateral meniscus, respectively (Robins, 1990; Evans & Hermanson, 1993). The menisofemoral ligament connects the caudal part of the lateral meniscus to the lateral surface of the medial femoral condyle, which allows the lateral meniscus to move more freely within the joint during motion (Arnoczky, 1993). In opposition, the medial meniscus is firmly attached to the tibial plateau with attachments to the medial collateral ligament and to the joint capsule via the coronary ligaments (Arnoczky, 1993; Vasseur 2003).

1.2. Cranial cruciate ligament

1.2.1. General macroanatomy

The CrCL originates as a fan-shaped ligament from the caudomedial aspect of the lateral femoral condyle (Stouffer, Butler & Kim, 1983) and runs, cranially, medially and distally in an outward spiral across the intercondylar notch to insert on the cranial intercondyloid area of the tibia (Arnoczky & Marshall, 1977). Functionally, the CrCL has two distinct bands: a smaller

craniomedial band and a larger caudolateral band (Arnoczky & Marshall, 1977; Heffron & Campbell, 1978). The craniomedial band is the most spiral and the longest, arising more proximally from the femur and inserting more cranially on the tibial attachment area compared to the caudolateral band (Arnoczky & Marshall, 1977; Heffron & Campbell, 1978). The craniomedial band is taut in flexion and extension and is commonly damaged, whereas the caudolateral band is taut in extension only and is less commonly injured (Arnoczky & Marshall, 1977).

1.2.2. General microanatomy and neurovascular supply

The cruciate ligaments are composed of a complex regulatory network of proteins, glycoproteins, viscoelastic fibres and glycosaminoglycans. The main protein found in their matrix is type I collagen. Other structural components of these ligaments are water, blood vessels and nerves, which are important for the proprioceptive feedback that controls stifle motion. These ligaments are covered by a fold of synovial membrane (Arnoczky, Rubin & Marshall, 1979), mainly of dense connective tissue, small fibroblasts and some adipocytes, being more cellular than the rest of the ligaments (Heffron & Campbell, 1978). The CrCL has histologic features of dense collagenous connective tissue with parallel bundles of fibers, formed by fibrils that are composed by repeated collagen subunits (Alm & Strömberg, 1974; Heffron & Campbell, 1978; Vasseur, Pool & Arnoczky, 1985), longitudinally oriented, intercalated predominantly with fibroblasts (Heffron & Campbell, 1978). These collagen fibers are organized in subfascicles which compose different sized fascicles. A fascicle can contain between 1 and 10 subfascicles (Heffron & Campbell, 1978; Yahia & Drouin, 1989).

As previously referred, branches of the middle genicular artery appear to give the most vascular contribution to the centre of the joint. The middle genicular artery arises from the popliteal artery and penetrates the joint capsule on its caudal aspect, passing craniodistally to the intercondylar fossa and running cranially between the cruciate ligaments. The blood supply to both cruciate ligaments is mostly of soft tissue origin (Arnoczky et al., 1979; Kobayashi et al., 2006), particularly from the infrapatellar fat pad and the well-vascularized synovial membranes, which form an envelope around the ligaments (Alm & Strömberg, 1974; Tirgari, 1978; Arnoczky et al., 1979; Kobayashi et al. 2006). There is an endoligamentous vascular network around and along the bundles of collagen fibres inside the ligaments that supports the connective tissue (Alm & Strömberg, 1974; Arnoczky et al., 1979). Also, microscopic holes,

detected by electron microscopy, in the synovial membrane covering the ligaments have been suggested to play a role in the ligament nutrition via the synovial fluid (Kobayashi et al., 2006). The mid-portion of the CrCL appears to be the less vascularised area of the ligament and the same is noted in the CaCL, although the later displays a greater abundance of periligamentous and synovial vessels than the CrCL (Tirgari, 1978; Arnoczky et al., 1979; Vasseur et al., 1985). There are three main articular nerves, which arise from the saphenous nerve, common peroneal nerve and tibial nerve. They are, respectively, the medial articular nerve - the largest of the stifle; the lateral articular nerve, which supplies the lateral aspect of the stifle joint; and the caudal articular nerve, which runs to the caudal aspect of the joint capsule where it communicates with branches of the medial articular nerve, though it is variably present in dogs (O'Connor & Woodbury, 1991).

The cruciate ligaments are covered by a peripheral synovium where nerves of various diameters spread on, with axons radiating through the interfascicular spaces, running along with the epiligamentous and endoligamentous blood vessels (Yahia, Newman & St Georges, 1992). This sensory network of the cruciate ligaments is important in the neurosensory system around the joint as it provides information about joint movement and position as well as noxious events (Johansson, Sjolander & Sojka, 1991; Miyatsu, Atsuta & Watakabe, 1993).

1.2.3. Functional anatomy

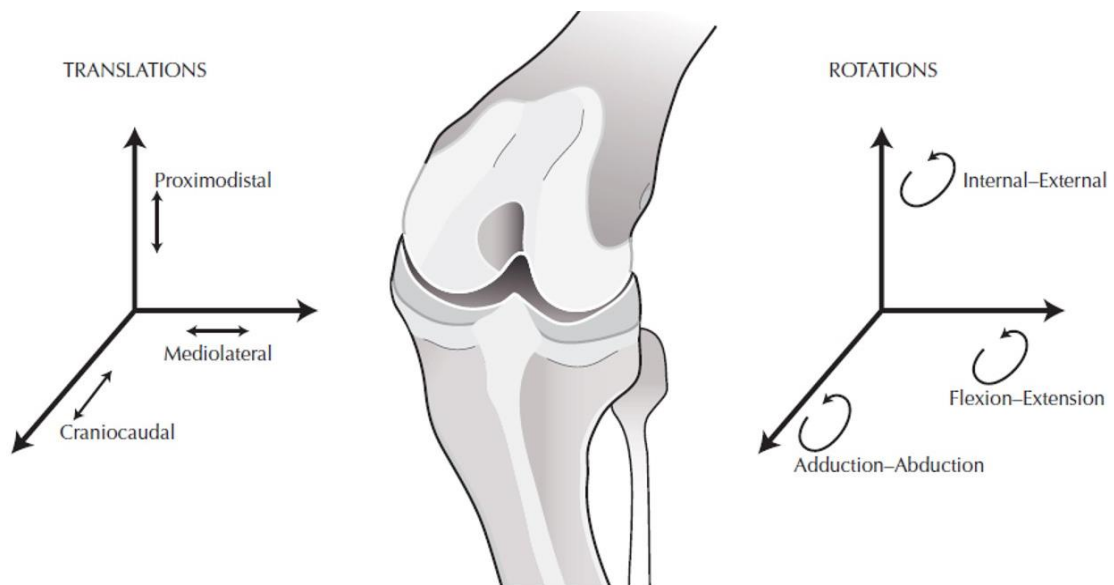
Roughly, during flexion the CrCL is relaxed and becomes taut in extension, whereas the CaCL is taut during flexion and remains relaxed in extension (Arnoczky & Marshall, 1977). However, the two bands that compose the CrCL do not have the same dimensions, functioning independently during flexion and extension (Arnoczky & Marshall, 1977). Therefore, during flexion, there is elongation of the craniomedial component and shortening of the caudolateral component (Arnoczky & Marshall, 1977; Heffron & Campbell, 1978). In contrast, when the stifle is in extension, both bands are taut (Arnoczky & Marshall, 1977; Heffron & Campbell, 1978). Diversely, in the CaCL, the cranial part is loose in extension and becomes taut during flexing, while the caudal part displays the opposite (Arnoczky & Marshall, 1977).

1.3. Biomechanics of the intact stifle

The stifle is a condylar joint, where the round femoral condyles articulate with the flat tibial condyles. The stifle allows motion in three planes, not functioning as a pure hinge joint. The

flexion-extension motion results from a combination of rolling and gliding of the femur on the tibia. Femorotibial contact translates more caudally on the lateral than on the medial plateau, resulting in tibial rotation during flexion (Vasseur & Arnoczky, 1981). Limited *varus* and *valgus* angulation may also occur during flexion since the collateral ligaments are loosen in this position. However, in extension both collateral ligaments function to minimise these two angulations of the tibia. Also, they function together with the cruciate ligaments to limit internal rotation of the tibia relative to the femur both in flexion and extension, representing the primary restraint in extension, whereas the cruciate ligaments provide primary check during flexion (Vasseur & Arnoczky, 1981; Slocum & Devine, 1983). In contrast, external rotation is constraint exclusively by the collateral ligaments (Vasseur & Arnoczky, 1981). Slight medial-lateral and proximal-distal tibial translation may also be seen but such movements are tightly constrained also by the collateral ligaments.

Figure 3: Drawing illustrating the six degrees of freedom of the femorotibial articulation. The femur and the tibia translate and rotate about the three axis shown in the drawing (From: Muir, P. Structure and Function, Advances in Canine Cranial Cruciate Ligament, 1st ed., 2010, p. 38.Wiley-Blackwell)



During flexion of the stifle, the craniomedial band of the CrCL is taut whereas the caudolateral band and the lateral collateral ligament are relaxed, allowing internal rotation of the tibia on the femur. Flexion is limited by contact between the musculature of the thigh and the tarsal region. During extension, both bands of the CrCL and the lateral collateral ligament are taut and external rotation of the tibia relative to the femur occurs. Extension is limited by contact between the CrCL and the intercondylar notch, preventing hyperflexion of the joint. The cruciate ligaments move independently as the stifle joint is flexed and extended although their

movement is coordinated to maintain the position of the tibia relative to the femur and thus keep it stable (Slocum & Slocum, 1993).

Joint motion also leads to motion of the menisci. Therefore, menisci slide caudally during flexion, particularly the lateral meniscus due to medial meniscus attachments to the medial collateral ligament and joint capsule (Arnoczky, 1993).

Due to the incongruence observed between the femoral condyles and the tibial plateau, the stifle stability relies on dynamic stabilisers, principally the quadriceps, hamstrings and gastrocnemius muscles, and on passive stabilisers, principally the cruciate ligaments, menisci, collateral ligaments and joint capsule (Pozzi & Kim, 2010; Hayes, Granger, Langley-Hobbs, & Jeffery, 2013).

The CrCL has three basic biomechanical functions: prevent the cranial drawer movement of the tibia relative to the femur; prevent overextension of the stifle and prevent excessive internal rotation of the tibia in relation to the femur. During flexion, there is elongation of the craniomedial band of the CrCL and shortening of the caudolateral component (Arnoczky & Marshall, 1977; Heffron & Campbell, 1978). Therefore, the former is the leading contributor in preventing craniocaudal translation during flexion. The caudolateral band only has this function when the craniomedial band is damaged or severely stretched (Wingfield, Amis & Stead, 2000). Conversely, when the stifle is in extension, both bands are taut and limit cranial translation of the tibia relative to the femur (Arnoczky & Marshall, 1977; Heffron & Campbell, 1978).

The cruciate ligaments also limit the internal rotation of the tibia relative to the femur during flexion (Arnoczky & Marshall, 1977; Harari, 1993) by being wrapped upon each other and spiral on themselves (Singleton, 1957; Arnoczky & Marshall, 1977), whereas in extension, the collateral ligaments are responsible for limiting rotation and the cruciate ligaments provide a secondary restraint (Singleton, 1957; Vasseur et al., 1985). With respect to the overextension, the caudolateral band of the CrCL acts as a primary and the CaCL as a secondary restraint (Singleton 1957; Arnoczky & Marshall, 1977).

The CaCL limits caudal tibial translation and helps limiting excessive internal-external rotation (Arnoczky & Marshall, 1977). The collateral ligaments prevent, primarily, *varus* and *valgus* angulation but in case of failure of these, the cruciate ligaments play the same role (Vasseur & Arnoczky, 1981). The menisci compensate the joint incongruence, acting as secondary stabilizers when there's integrity of the primary stabilizers, particularly the CrCL.

The function of the stifle is influenced by pelvic limb musculature. These muscles represent the dynamic stabilizers of the joint, resultant of simultaneous contraction (co-contraction), mediated by the nervous system. They include the quadriceps muscle group, the caudal thigh

muscle group, including semimembranosus, semitendinosus and biceps femoris, and the extensor group, comprising gastrocnemius and superficial digital flexor (Slocum & Slocum 1993).

Considering the forces created by weight-bearing and the musculature of the pelvic limb, during the weight bearing phase of the gait cycle, the anatomically caudally sloped tibial plateau relative to the tibial long axis result in a cranially directed shear force on the tibia within the stifle joint, which is typically referred to as the cranial tibial thrust. Thereafter, during weight bearing, by compression of the femoral condyles against the tibial plateau, the forward movement of the tibia relatively to the femur would be expected if a passive restraining was absent. This movement is prevented by the CrCL. The magnitude of cranial tibial thrust is dependent on both the degree of compression during weight-bearing, which is related to the size and activity level of the dog, and the tibial plateau angle, which slopes caudodistally and varies between dogs due to anatomical and conformational differences (Warzee, Dejardin, Arnoczky & Perry, 2001).

2. CRANIAL CRUCIATE LIGAMENT DISEASE

2.1. Pathogenesis

Initially, cranial cruciate rupture in dogs was thought to be consequence of traumatic injury. However, the high risk of contralateral CrCL rupture observed in affected dogs combined with the non-concordant clinical histories of the patients, gave risen to new theories of the ethiopathology of the CrCL disease which has been studied since then. Although it is a fact that a traumatic injury can cause an acute CrCL rupture, studies have suggested that most cases of CrCL rupture result from chronic degenerative changes within the ligament (Vasseur et al., 1985; Hayashi et al., 2003). These changes develop through gradual degeneration of the CrCL, inflammation of the stifle joint, partial rupture and, finally, complete rupture of the CrCL. In the beginning, changes may not cause lameness but they can create mild joint instability endorsing osteoarthritis development (Muir, 2010).

Currently, CrCL injury in the dog, is more commonly considered a multifactorial complex problem which involves a detailed understanding of the biomechanics of the stifle joint and functional anatomy, conformation and gait analysis in order to achieve successful treatment. Therefore, treatment should be based on managing the underlying anatomical and conformational variances rather than classically struggling to eliminate tibial cranial drawer movement (Jerram & Walker, 2003).

Denny and Butherworth (2000) divided dogs with CrCL disease in four main groups, according to aetiology:

1. CrCL rupture by traumatic injury, which is very unlikely but can occur in cases of overextension of the stifle or excessive internal rotation during intensive exercise.
2. CrCL degenerative disease in adult dogs, which is the most common cause of CrCL disease and affects mainly dogs between 5 and 7 years old. The dog may show a low grade of lameness if there is a partial rupture that progresses to a complete rupture triggered by normal exercise resulting in a higher grade of lameness. At this stage there are often osteoarthritic changes already.
3. CrCL rupture in young large breed dogs (Bennett et al., 1988), mostly seen in dogs between 6 months and 3 years and resulting from early degenerative changes that may be related to the stifle and hindlimb conformation.
4. CrCL rupture associated with inflammatory arthropathies. In presence of immune-mediated or infective inflammatory arthropathies changes can develop within the ligament leading to its rupture.

Breed has been reported to be predisposing factor to degenerative disease of the CrCL (Guthrie, Keeley, Maddock, Bright & May, 2012; Taylor-Brown et al., 2015). Also, a recent study has shown a significant genetic component associated with canine CrCL rupture (Baird, Carter, Innes, Ollier & Short, 2014). Excessive caudal slope of the tibial plateau leads to an increased cranial thrust of the tibia, resulting in increased stress in the CrCL (Slocum & Devine, 1984). Dogs with CrCL injuries have been reported to have significantly greater TPA than dogs without CrCL injury (Morris & Lipowitz, 2001). However, recent studies reveal that there seems to be no relationship between the angles of the proximal tibia and the CrCL rupture in dogs (Arruda, Muzzi, Muzzi, Júnior, Oberlender & Silva, 2015). Stenosis of the intercondylar notch of the femur is thought to contribute to CrCL rupture due to the impingement of the medial aspect of the lateral condyle of the femur on the CrCL (Lewis, Allen, Henrikson & Lehenbauer, 2008). Obesity, inactivity in puppyhood and repetitive chronic trauma can also be factors that enhance the chances of developing CrCL disease (Corr, 2009). Often, the layers that compose the stifle joint capsule are hyperplastic with lymphoplasmacytic synovitis in dogs that have naturally occurring CrCL rupture; thus, a possible underlying immune-mediated component may be involved in spontaneous CrCL rupture (Galloway & Lester, 1995). Dogs with early CrCL disease are usually presented with lameness, stifle joint effusion and synovitis though they often have a stable joint clinically. On the contrary, complete CrCL rupture results in evident instability of the stifle joint, leading to a more severe degree of

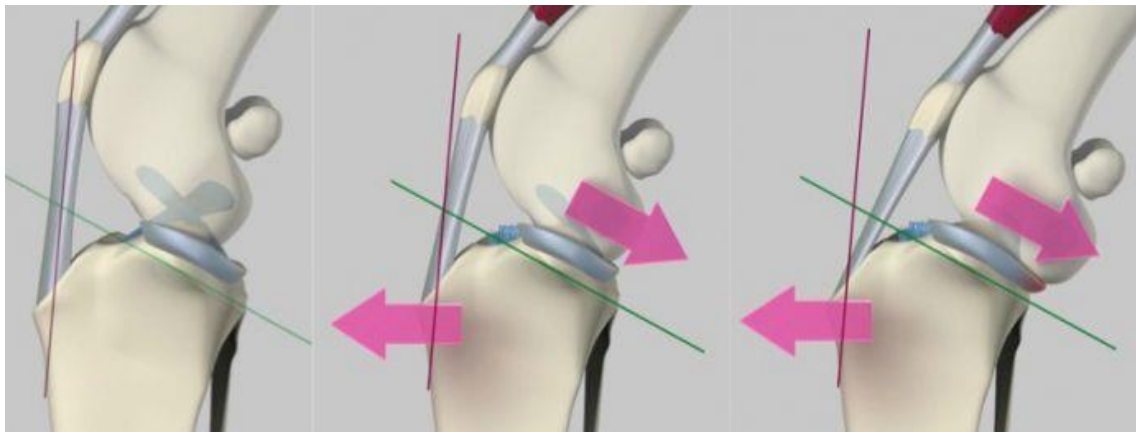
lameness and joint pain as well as progressive degenerative changes within the joint with periarticular osteophyte formation and fibrosis, capsular thickening and meniscal damage. The progression of periarticular fibrosis may help stabilizing the joint but it does not improve the dynamic instability significantly (Tashman, Anderst, Kolowich, Havstad & Arnoczky, 2004).

2.2. Biomechanics of the CrCL-deficient stifle

In the CrCL-deficient stifle, because of the caudally oriented tibial plateau with respect to the tibial mechanical axes, force generated in the stifle joint acts to translate the tibia cranially during weight bearing (Warzee et al., 2001; Slocum & Devine, 1983). Increased cranial tibial translation is consistently identified following CrCL rupture and, as shown in a study of experimental sectioning of the CrCL, it can reach 10 mm on average (Korvick, Pijanowski & Schaeffer, 1994; Tashman et al., 2004). However, in spontaneously occurring CrCL rupture cranial tibial translation may not reach such values, as a consequence of periarticular fibrosis (Pozzi & Kim, 2010). Quadriceps contraction has been suggested as being one of the factors that lead to cranial tibial translation during the stance phase (Korvick et al., 1994; Tashman et al., 2004). In the absence of restraint by the CrCL, the medial meniscus acts as a primary stabilizer working as a wedge that opposes to femoral condyle translation and rotation, which justifies its common injury (Pozzi et al., 2006). The lateral meniscus does not provide such function because of its mobility, which results in its protection from impingement and tearing. Also the collateral ligaments and the joint capsule act as passive stabilizers in this case. Dogs with CrCL resort to adapting mechanisms as a result of the neuromuscular response to pain induced by joint instability. These mechanisms result in a decreased loading of the affected limb, carrying it more flexed during gait cycle (Korvick et al., 1994; DeCamp et al., 1996; Tashman et al., 2004; Ragetly, Griffon, Mostafa, Thomas & Hsiao-Wecksler, 2010). Also, during the swing phase, flexion angles of the stifle joint do not allow the quadriceps to induce cranial tibial luxation, which suggests a CrCL-independent phase (Korvick et al., 1994; Tashman et al., 2004). The instability generated at the CrCL-deficient stifle, due to the increased tangential shear forces and abnormal contact mechanics (Pozzi et al., 2006; Anderst & Tashman, 2009), is strongly related to the progression of OA (Pozzi & Kim, 2010). Cranial cruciate ligament transection results in tibial internal rotation (Warzee et al., 2001; Kim, Pozzi, Banks, Conrad & Lewis, 2009). However, tibial internal rotation was not a significant change after CrCL loss in *in vivo* investigations, which suggests that internal rotation restraint is

dictated by bony geometry, muscle forces and soft tissue constraints, instead of CrCL (Tashman et al., 2004).

Figure 4: Mechanics of the CrCL-deficient stifle: during weight-bearing, the compressing forces acting on the stifle joint result in a cranial tibial translation, due to the caudally sloped tibial plateau. (From: Fitzpatrick Referrals (2011) *Cruciate Ligamente Disease or injury – Fitzpatrick Referrals*. Accessed June 2016, in <http://www.fitzpatrickreferrals.co.uk/orthopaedic/cranial-cruciate-ligament-injury/>)



2.3. Meniscal tears

Meniscal injuries are often seen concomitantly with CrCL rupture or as a consequence of such condition (Ritzo, Ritzo, Siddens, Summerlott & Cook, 2014). Conservative treatment is not recommended because most meniscal tears affect the avascular portion of the cartilage so, healing is unlikely to occur (Williams, Tomlinson & Constantinescu, 1994). Therefore, surgical management is required when these structures are damaged and failure to appropriately manage meniscal injuries is a common reason for poor outcome of a surgical procedure (Case, Hulse, Kerwin & Peycke, 2008). The medial meniscus is most commonly affected due to its anatomic involvement. The caudal horn of the medial meniscus is attached to the tibial plateau, moving with this bone underneath the femur during cranial drawer movement when there is failure of the CrCL. The impingement of the femur on the caudal horn can cause different types of damage which can be broadly classified based on their appearance into radial, vertical longitudinal (capsular detachment), bucket handle, flap and complex meniscal tears (Thieman, Pozzi, Ling, Lewis & Horodyski, 2009), with the most common lesion being a bucket handle tear (Ritzo et al., 2014). The lateral meniscus is rarely injured due to its attachment to the femur that allows it to move with this bone avoiding impingement (Vasseur, 2003). However, arthroscopic

assessment of 100 canine stifles revealed a strong association between CrCL injury and lateral meniscal injuries, therefore, although clinical importance of such injuries is still not known, examination of both menisci should always be performed (Ralphs & Whitney, 2002).

Diagnosis and treatment can be, preferably, achieved by arthroscopy (Pozzi, Hildreth and Rajala-Schultz, 2008). However, arthrotomy also allows meniscal examination and surgery. For that purpose, the stifle joint should be flexed and the patella reflected or retracted (Pozzi et al., 2008). Most meniscal tears found in dogs with CrCL disease involve the avascular portion of the meniscus (Thieman et al., 2009) and therefore, these lesions are treated by resection of the affected area via partial, hemi- or complete meniscectomy. Although these procedures have been reported to cause progress of osteoarthritis in normal dogs (Johnson, Manley, Chu, Francis & Catterson, 2004) probably due to a loss of stabilization by the meniscus (Kim, Lewis & Pozzi 2012) and to alterations in pressure distribution (Pozzi et al., 2008; Thieman, Pozzi, Ling & Lewis, 2010), partial meniscectomy has been shown to cause less degenerative joint changes when compared with complete meniscectomies (Johnson et al. 2004). However, total meniscectomies result in a reduced risk of iatrogenic tear of the cartilage in the joint or of the CaCL (Austin, Montgomery, Wright, Bellah & Tonks, 2007). Failure to detect and correct meniscal injuries during initial assessment of the CrCL disease can lead to complications following surgery and be the cause of persistent lameness (Case et al., 2008).

2.4. Epidemiology

CrCL injury is the most commonly diagnosed orthopaedic condition of the stifle in dogs (Dupuis & Harari, 1993; Harari, 1995; Moore & Read, 1996; Vasseur, 2003). The most recent literature show that dogs over 3 years of age have increased chances of diagnosis of CrCL rupture than dogs under 3 years (Taylor-Brown et al., 2015). Previously, other studies revealed that the peak of incidence most commonly reported was in dogs between 2 and 10 years of age (Whitehair, Vasseur & Willits, 1993; Duval, Budsberg, Flo & Sammarco, 1999; Powers, Martinez, Lincoln, Temple & Arnaiz, 2005; Harasen, 2008, Witsberger, Hahn, Cook, Villamil & Schultz, 2008). Nevertheless, after first diagnosing CrCL rupture in a dog, the probability of the contralateral stifle become affected is 22%-61% (Doverspike, Vasseur, Harb & Walls, 1993; Moore & Read, 1995; de Bruin, Rooster, Bree & Coz, 2007; Cabrera, Owen, Mueller & Kass, 2008; Buote, Fusco & Radasch, 2009).

Neutered males and neutered females have been reported to have significantly increased odds of developing CrCL rupture compared with intact dogs of both genders (Whitehair et al., 1993,

Duval et al., 1999; Witsberger et al., 2008, Taylor-Brown et al., 2015). Also, early neutering (before 6 months of age) has been considered a significant risk factor for development of excessive tibial plateau angles in large-breed dogs with CrCL rupture and it was suggested that excessive TPA might contribute to earlier degeneration of the CrCL (Duerr et al., 2007).

Breeds that are more prone to develop CrCL rupture include medium, large and giant breeds, particularly Newfoundlands, Rottweilers, Labrador Retrievers, Bulldogs and Boxers (Witsberger et al., 2008). On the other hand, chondrodystrophoid, small and hound breeds like Miniature Dachshund, Dachshund, Miniature Schnauzer, Greyhound, Shih Tzu and Pekingese are very unlikely to being diagnosed with CrCL rupture (Witsberger et al., 2008). The prevalence noted on these breeds suggests a genetic component to etiopathogenesis of CrCL rupture. Also, hip dysplasia in dogs is a genetic disorder which prevalence is reported in many of the same breeds, often concurrent with CrCL disease, which contributes even more to the thought of a genetic involvement in the disease (Powers et al., 2005; Wilke et al., 2006; Witsberger et al., 2008). Based on this, a gene study revealing significant genetic associations with canine CrCL rupture for the first time, was recently published, indicating that the strength and stability of the CrCL may be compromised by mutations leading to increased risk of CrCL disease (Baird et al., 2014).

2.5. Clinical history

Owners may provide a history suggestive of trauma. However, the large majority of dogs do not have a history of obvious trauma and further investigation will often reveal an insidious onset of lameness or an incident of minor trauma, which led to lameness (Muir, 2010). In other, uncommon, cases, owners can give a clear history of major trauma which suggests a traumatic rupture of the CrCL that sometimes are accompanied of avulsion fracture of cruciate ligament attachment site. However, CrCL avulsions are rare and occur mostly in young dogs. In these cases, the ligamentous attachment to the bone is stronger than the immature bone itself, resulting in avulsion due to a force which is not sufficient to cause ligament rupture (Reinke, 1982).

The duration of lameness reported by the owners is extremely variable. Also, owners often describe a weight-bearing lameness that tends to get worse after exercise and sometimes they may refer an audible clicking while walking, which can be indicative of meniscal damage (Muir, 2010).

Frequently, patients with partial tear of the CrCL will be presented with a more subtle pelvic lameness, sometimes bilateral, usually continuous and not responsive to NSAID therapy (Muir, 2010). Owners may report a stiff pelvic limb gait. In such cases, arthritis is likely to have developed but the stifle is stable (Muir, 2010).

2.6. Clinical signs

The clinical signs in dogs with CrCL disease are rather variable. The lameness level and the onset may differ from case to case, depending on the degree of damage to the ligament and the menisci (Muir, 2010). Some dogs may be completely non-weight-bearing, more commonly following an acute CrCL rupture as there is acute inflammation and haemarthrosis, in which case, if rest and appropriate pain relief are provided, the dog may improve significantly and begin to bear weight on the affected limb within 2 to 3 weeks but intermittent periods of lameness may recur due to ongoing inflammation and joint instability. However, most dogs with CrCL disease are typically weight-bearing and will have intermittent but slowly worsening lameness, which improves with rest but recurs once exercise is reintroduced, becoming more and more persistent (Johnson & Johnson, 1993; Piermattei, Flo & DeCamp, 2006). Dogs with early cruciate disease may have little to no palpable instability of the stifle joint with only mild disruption of the CrCL, often presented with lameness and joint effusion. If the disease is bilateral, dogs will usually lean forward with the purpose of unloading the pelvic limbs (Muir, 2010). In regards to onset, most dogs show a gradual progression of lameness, over weeks or months. Conversely, some dogs are relatively normal and suddenly become acutely non-weight-bearing. A clinical sign that can be quite frequently seen in dogs with CrCL rupture is the inability to sit straight and square. They often position the affected limb externally rotated and reducing stifle flexion and so, the calcaneus is not directly underneath the tuber ischia (Muir, 2010). This external rotation may also be evident during walking. Also, an audible clicking can sometimes be heard during walking, suggesting meniscal damage, typically concurrent with CrCL rupture. Muscle atrophy is also generally apparent on the affected pelvic limb (Muir, 2010).

In dogs with bilateral CrCL rupture, neurological disease can primarily be suspected due to the patient's difficulty in rising from a sitting to a standing position. Therefore, a thorough physical exam should be carefully performed (Muir, 2010).

A thorough orthopaedic exam is warranted and generally begins with the dog in a standing position, allowing comparison with the contralateral limb. Palpation and examination of the

stifle joint can provide imperative findings that certainly help in the diagnosis of CrCL failure, such as joint effusion, detectable immediately caudal to the patellar ligament, making it difficult to distinct the patella tendon on palpation because the joint capsule bulges out on either side of the ligament. This becomes more obvious if the animal is bearing weight on the affected limb during palpation. Though, sometimes the effusion is not very abundant and so may not be detected on palpation. In such cases radiography may be a better diagnostic test to evaluate the presence of joint effusion (Muir, 2010), which is identified as a disruption of the outline of the infrapatellar fat pad and distension of the joint capsule (Denny & Butterworth, 2000).

Presence of medial buttress is highly indicative of CrCL rupture (Vasseur, 2003). It consists of a firm thickening on the medial aspect of the stifle detected on palpation, subsequent to periarticular fibrosis. Palpation of both pelvic limbs can reveal muscle atrophy of the gluteal and quadriceps musculature of the affected limb, particularly in chronic cases (Vasseur, 2003). With the dog in lateral recumbency, manipulation of the stifle joint may demonstrate crepitation, meniscal “clicking” and pain while eliciting flexion and extension. Range of motions can also be evaluated and may be increased or decreased, depending on the chronicity of the injury (Moore & Read, 1996; Johnson & Hulse, 2002; Vasseur, 2003)

There are two specific tests that can be performed in order to assess craniocaudal instability between the tibia and the femur. These are the cranial drawer test and the cranial tibial thrust test and they are best performed with the patient in lateral recumbency with the affected limb on an upward position (Henderson & Milton, 1978; Muir, 1997). The former requires placing the thumb of one hand on the lateral fabella, with the index finger on the patella and placing the thumb of the other hand on the caudal tibial plateau, with the index finger on the tibial tuberosity. Then, the tibia should be moved cranially relatively to the femur. A positive result is given by a movement in this direction with a poorly defined end point. In dogs with chronic CrCL disease, where there is periarticular fibrosis and sometimes medial meniscal damage blocking cranial tibial translation, and also in dogs with partial CrCL rupture, this test can result in a false negative (Flo & DeYoung, 1978). Moreover, if there is only rupture of the craniomedial band of the CrCL, the cranial drawer sign will only be identified when the stifle is partially flexed (Scavelli, Schrader, Matthiensen & Skorup, 1990; Strom, 1990). Immature dogs may demonstrate a small degree of cranial drawer sign but the end point remains well defined. This is considered normal and is suggestive of slight laxity of the ligament. However, dogs very rarely injure the CrCL prior to completion of skeletal growth so, in that case, radiographic examination should follow to rule out bony injury such as avulsion of the tibial crest or fracture of the distal femoral physis (Reinke, 1982).

The cranial tibial thrust is performed with the stifle at a normal standing angle (120°), placing the thumb of one hand on the lateral fabella and the index finger on the tibial tuberosity. The other hand should grab the metatarsus and elicit flexion of the hock with the stifle fixed in position. The compression on the tibia, triggered by the hock flexion, results in a cranial push of the proximal tibia. In presence of CrCL failure a cranial tibial translation will be noted by the increased gap between the thumb and index finger (Moore & Read, 1996).

Dogs tend to tolerate the cranial tibial thrust well, allowing its execution without sedation or anaesthesia. Conversely, the cranial drawer test is not so bearable, especially in patients with recent rupture due to pain and muscle spasm. It is also a more difficult test to perform in large breed dogs. Therefore, although cranial drawer test can be achieved in conscious animals, in these cases, sedation or anaesthesia is frequently required (Corr, 2009). Assessing stifle instability under sedation or general anaesthesia is extremely helpful to ensure that subtle instability has not been missed during physical examination for example due to muscle contraction, but principally in dogs with chronic stifle disease, where periarticular fibrosis can reduce cranial drawer sign (Pozzi & Kim, 2010).

2.7. Diagnostic imaging

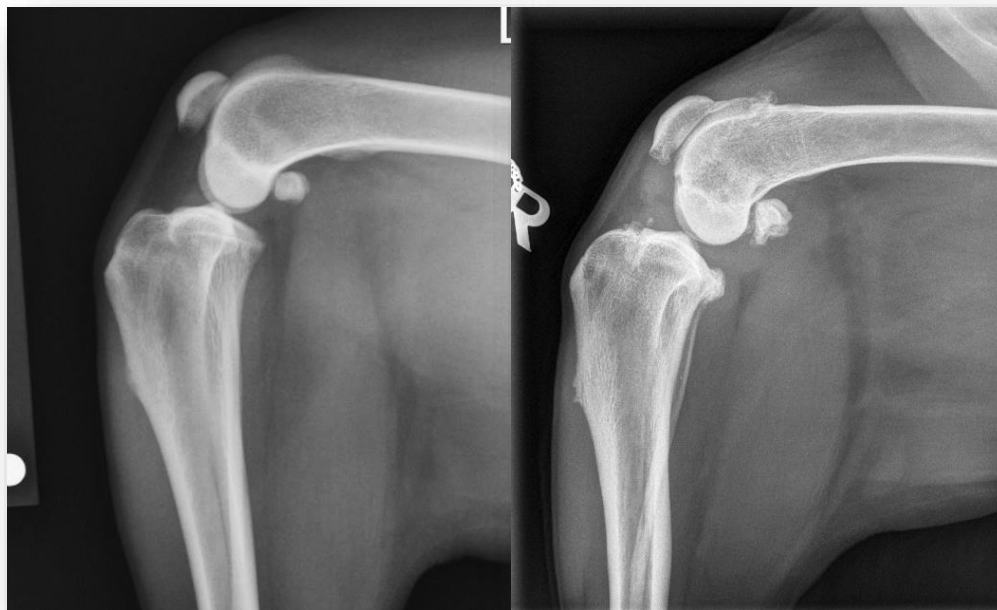2.7.1. Radiography

CrCL rupture is generally appraised by physical examination. As has been previously described, a series of clinical signs can be identified. Stifle instability should be assessed through cranial drawer test or cranial tibial thrust, preferably under sedation or anaesthesia for a more accurate evaluation, given the fact that such tests have been associated with low sensitivity and specificity when performed on conscious animals (Carobbi & Ness, 2009). Although these tests are helpful while identifying stifle joint instability, they are not definitive.

In radiographic examination, it is important to take into consideration that radiographic changes are non-specific and mainly correspond to changes secondary to CrCL disease (Denny & Butterworth, 2000). Nevertheless, radiographic examination is very useful in these cases in order to confirm stifle pathology, evaluate the degree of osteoarthritic changes and ensure there are no other obvious causes of lameness that may be designated on the list of differential diagnostics, such as neoplasia or bone fracture (Kowaleski et al., 2012). Both stifles should be radiographed for comparison (Vasseur, 2003). Mediolateral and craniocaudal projections of the stifles are useful to detect synovial effusion which is identified by partial or complete

replacement of the infrapatellar fat opacity by a soft tissue opacity and by distension of the joint capsule, mostly observed caudally (Denny & Butterworth, 2000).

Figure 5: (Left) Mediolateral radiographic view of a normal stifle (From: Benjamino, K. (2012) *ACL injuries in dogs*. Accessed June 2016, in <https://drbenjamino.com/category/tplo/> (Right) Mediolateral radiographic view of a stifle with complete rupture of the CrCL, presence of joint effusion and osteoarthritis can be identified (Dispensed by Dr. Robinson, KVG).



Osteoarthritis develops with CrCL disease and so, periarticular osteophytes are likely to appear primarily around the proximal margins of the trochlea and poles of the patella. Later, they can be detected also around the fabellae and the edges of the tibial plateau. Enthesopathy at insertion of CrCL can also often be identified and sometimes bone fragments may be present inside the joint in avulsion injuries of the CrCL. In more advanced cases, sclerosis of subchondral bone and soft tissue mineralization can be seen (Denny & Butterworth, 2000).

Tibial compression radiography was developed to confirm CrCL rupture by measuring relative displacement of bony landmarks on paired lateral radiographs (neutral and tibial compression) (de Rooster, Van Ryssen & Van Bree, 1998). For this purpose, the dog should be positioned in lateral recumbency and a standard lateral radiography is first taken in a neutral position (90° of flexion). Then, maintaining the stifle joint in the same angle of flexion, the tarsal joint is flexed to its maximum by manual pressure and the second radiography is taken in tibial compression position. Afterwards, both radiographies are compared and when the tibia is moved cranially in relation to the femur in the stressed view, a CrCL rupture is present. Tibial compression

radiography has a high sensitivity and perfect specificity identifying both partial and complete CrCL rupture (de Rooster et al., 1998). Therefore, it is a useful technique to confirm a tentative diagnosis of CrCL damage, particularly when the cranial drawer sign is not obvious on physical examination (de Rooster et al., 1998).

2.7.2. Ultrasonography

Ultrasound examination of the stifle is a non-invasive method that allows evaluation of soft tissue structures in the joint, which can help diagnosing stifle pathology (Muzzi, Muzzi, Rezende & Rocha, 2001). A high frequency linear transducer is most appropriate because allows a highly detailed image of superficial structures, minimizing artefacts from anisotropy that occur when the fibres of the ligaments are not perpendicular to the ultrasound beam (Reed, Payne & Constantinescu, 1995; Kramer, Stengel, Gerwing, Schimke & Sheppard, 1999). To scan the cranial, caudal and lateral aspects of the stifle, the dog should be in lateral recumbency with the affected limb in an upward position and then, the patient is turned over for easier access to the medial aspect of the joint. A dynamic examination can be performed by flexing, extending and rotating the stifle (Arnault et al., 2009).

Ligament disorders can sometimes be detected ultrasonographically. In order to get the best view of the cruciate ligaments, a flexed infrapatellar probe position should be used. Healthy CrCL is hypoechoic on ultrasound scan, whereas when there is chronic rupture it is seen as a hyperechoic area close to the insertion of the tibia. Around it, hypoechoic haematoma and inflammation can be identified. In contrast, acute ruptures are not so easily detected due to the small size of the ligaments and sometimes only a small anechoic haematoma in the traumatized area can be identified. The menisci can also be visualized in the medial and lateral regions and high specificity and sensitivity has even been associated with diagnosis of bucket handle tears of the medial meniscus via ultrasonography (Mahn, Cook, Cook & Balke, 2005). A healthy meniscus appears as a triangular structure of homogeneous, medium echogenicity, between the femoral condyle and the tibial plateau, whereas when damaged, it becomes heterogeneous, with hyperechoic and hypoechoic areas, often seen as a hyperechoic double line in the parenchyma (Arnault et al., 2009).

Radiography allows a better characterization of the osteoarthritis than sonography (Gnudi & Bertoni, 2001). Nevertheless, subchondral irregular defects in the hyperechoic bone surface can be recognized as osteoarthritic changes, on ultrasound scan. In chronic osteoarthritis the joint capsule appears as a hyperechoic thickened structure and joint effusion as a hypoechoic to

anechoic area between the capsule and the bone surface. In the stifle joint, osteoarthritis is best seen in the suprapatellar and the infrapatellar regions (Arnault et al., 2009).

The use of ultrasound in determining stifle pathology may reveal quite helpful but it requires great training and experience of the imagist in musculoskeletal ultrasound (Arnault et al., 2009).

2.7.3. Computed tomography

Computed tomography (CT) is extremely sensitive in demonstrating calcified and bony structures and also allows visualization of the soft tissue. It is based on cross-sectional imaging and is particularly useful in identifying structures inside the joint that are superimposed, which is something impossible to achieve with radiography. Computed tomography arthrography (CTA) has shown accuracy in diagnosing CrCL rupture (Han et al., 2008) and medial meniscal injuries (Tivers, Commerford & Owen, 2009; Tivers, Mahoney & Corr, 2008). Tivers et al. (2008) demonstrated a sensitivity of 90% and specificity of 100% of dorsal CTA images for the diagnosis of simulated injuries of the caudal horn of the medial meniscus in cadavers. However, Samii et al. (2009) proved CTA was sensitive and specific in detecting CrCL abnormalities but had questionable accuracy in identifying meniscal injuries from transverse CTA images. Later, Tivers et al. (2009) showed that stifle dorsal plane CTA has potential for diagnosis of injuries of the medial meniscus in dogs. These results support the use of dorsal plane scans over transverse scans for investigation of meniscal injuries (Tivers et al., 2009). Also, it has been suggested that CTA allows identification of partial CrCL ruptures in dogs (Han et al., 2008). Moreover, CT appears to be of great value in the diagnosis of CrCL avulsion in young dogs (Gielen, Saunders, van Ryssen & van Bree, 2011).

2.7.4. Magnetic Resonance Imaging

Magnetic resonance imaging (MRI) is a well-established diagnostic method for detecting internal abnormalities of the human knee with high accuracy (Oei, Ginai & Hunink, 2007). It can detect early arthropathy, help directing treatment decisions and predicting a more detailed prognosis. It has been demonstrated that MRI is accurate in diagnosing canine meniscal injuries and providing useful information in the evaluation of CrCL injury (Barrett, Barr, Owen & Bradley, 2009; Blond, Thrall, Roe, Chailleux & Robertson, 2008; D'Anjou et al., 2008). However, due to costs and additional anaesthesia time required for such procedure, it is not an option in most cases, given the lack of evidence that it improves patient care when compared

to other more cost-effective diagnostic methods. Besides, in humans, arthroscopy has been suggested to be more accurate and, therefore, should be considered the gold standard for definitive diagnosis of cruciate and meniscal damage (Nikolaou et al., 2008). Yet, MRI provides valuable information of lesions in the subchondral bone, articular cartilage, and excellent discrimination between intact and torn menisci or to detect other cause of lameness which may not have been diagnosed by other methods (Blond et al., 2008).

2.7.5. Arthroscopy

Currently, in veterinary medicine, arthroscopy is a readily available method which provides a means of assessing and treating joint pathology, allowing complete visualization with magnification and precise manipulation of intra-articular structures, while being minimally invasive, with low morbidity intra- and postoperative associated (Ralphs & Whitney, 2002; Siemering, 1978; Kivumbi & Bennett, 1981). Therefore, It is becoming the method of choice for evaluation of the joint (Whitney, 2003). Magnification is one of the advantages arthroscopy offers over arthrotomy, particularly useful to detect some partial CrCL tears that often cannot be identified with the naked eye (Whitney, 2003). Diagnosis of a partial CrCL tear is important since surgical intervention in an early stage, before complete rupture of the ligament, may not only diminish the severity of future osteoarthritis but also allow preservation of the integrity of the remaining ligament fibres, which contributes to reducing the chances of developing meniscal disease (Whitney, 2003).

Also, visualization of the menisci is facilitated with arthroscopy as the arthroscope can be positioned directly adjacent to the meniscus in cranial and caudal joint compartment, providing a better perception of the integrity of these structures, allowing diagnosis and treatment of meniscal tears (Pozzi et al., 2008; Beale & Hulse, 2010; Kowaleski et al. 2012). Two clinical studies of dogs with CrCL disease showed that detection of concurrent meniscal diseases is 1.5 to 2 times more likely via arthroscopy than arthrotomy (Plesman, Gilbert & Campbell, 2013; Ritzo et al., 2014). However, probing with a meniscal probe has been found to improve the diagnostic ability of evaluations conducted via caudomedial or craniomedial arthrotomies as well as arthroscopy (Pozzi et al., 2008). Meniscectomy can be performed with the aid of a Hohmann retractor or a stifle distractor (Böttcher, Winkels & Oechtering, 2009; Pozzi et al., 2008). Early osteoarthritic changes to articular cartilage can also be identified arthroscopically but often will be missed with the naked eye (Beale & Hulse, 2010).

Arthroscopy can also be combined with arthrotomy, which provides a less invasive approach when compared with traditional arthrotomy and is easier to perform than the traditional arthroscopy. In this case, the arthroscope is introduced in the arthrotomy incision and delivers amplified and more detailed view of the intra-articular joint as previously described. Also, the arthroscopy instruments can all be placed on a single incision and the probability of fluid extravasation to the surrounding soft tissues is lower (Beale & Hulse, 2010). Arthroscopic-assisted arthrotomy is a valuable technique which allows more precise evaluation of the stifle joint and accurate treatment, with decreased pain and earlier return to function (Beale & Hulse, 2010).

3. TREATMENT OF CRANIAL CRUCIATE LIGAMENT RUPTURE

3.1. Conservative management

Although surgical treatment appears to be the most favourable choice for CrCL rupture as a mean to minimize joint instability and progression of degenerative joint disease (Vasseur, 2003; Piermattei, Flo & DeCamp, 2006), not all dogs are surgical candidates either due to age, health condition, body score or owners' financial constraints. In these cases, conservative management is required in order to relieve clinical signs. Dogs weighing less than 15 Kg seem to be more suitable for conservative management (Vasseur, 2003; Edge-Hughes & Nicholson 2007). A multimodal therapy is used to alleviate pain originated by osteoarthritis, reduce its progression and improve limb usage (Jaeger & Budsberg, 2010) and relies on the synergism provided by the combination of analgesics, chondroprotective agents, weight reduction and exercise restriction, which allow a decrease of clinical signs of pain (Lipowitz, 1993). Improvement is seen when nonsteroidal anti-inflammatory drugs (NSAIDs) are administered. Though, there is evidence that NSAIDs do not always provide complete pain relief in dogs with osteoarthritis (Lascelles & Main, 2002; Vasseur et al., 1995). Therefore, a combination of NSAIDs and adjunctive analgesics can be used in such patients. NSAIDs' side effects are well known and include gastritis, nephrotoxicity, decreased platelet aggregation and gastrointestinal ulceration. Also, there is evidence that some NSAIDs accelerate cartilage degeneration by suppression of chondrocyte proteoglycan synthesis where osteoarthritis has been established (Brandt, 1987). Yet, other NSAIDs show no adverse effects on cartilage synthesis, such as piroxicam, or increase the matrix component synthesis and protect the chondrocytes against apoptosis, such as meloxicam, and are often used in the medical management of osteoarthritis. However,

NSAIDs incompletely suppress the inflammatory process through a limited mechanism of action, therefore, they are not completely effective controlling clinical signs of OA and a multimodal regimen, including additional analgesics with different mechanisms of action, is often recommended in order to enhance pain management (Lascelles et al., 2008). Drugs such as tramadol, amantadine or gabapentin are often added to the treatment, in conjunction to NSAIDs (Lambert et al., 2004; Lascelles et al., 2008; Jaeger & Budberg, 2010).

Corticosteroids are effective in treating acute inflammation but their secondary effects, which may include spontaneous tendon or ligament rupture and also the fact that they enhance the rate of joint deterioration by inhibition of proteoglycan and cartilage biosynthesis, make them a last resort for dogs with CrCL disease (Hossain, Park, Choi & Kim, 2008; Kotnis, Halstead & Hormbrey, 1999; Chrysis, Zaman, Chagin, Takigawa & Savendahl, 2005).

Chondroprotective agents are thought to stimulate proteoglycan and hyaluronic acid synthesis as well as inhibit proteases in the synovial fluid and so, constitute a resource which may help controlling the progression of osteoarthritis in dogs (Dearmin, Trumble, Garcia, Chambers & Budberg, 2014). Also, nutraceuticals and dietary supplements may be added to the analgesic therapy (Jaeger & Budberg, 2010).

Overweight dogs put a lot of stress on their joints, therefore, restricted diet should be recommended in order to decrease weight-bearing (Marshall et al., 2010; Mlacnik et al., 2006). Exercise may also be restricted to reduce trauma-induced inflammation in the joints. Short walks (10 minutes) on a leash for 6 to 8 weeks may contribute to regain satisfactory limb function in some cases (Vasseur, 1984). However, physiotherapy may be beneficial. It can include controlled exercise, such as swimming, proprioceptive training and exercises of range-of-motion which help maintaining cartilage nutrition, muscle strength and cardiovascular function (Mlacnik et al., 2006; Vasseur, 2003). Nevertheless, therapy must be adjusted for each individual case, taking in account the degree of osteoarthritis, the patient's clinical signs and the dog's response to a certain type of treatment because these factors are fairly variable between different animals thus one treatment may not be suitable for all cases (Jaeger & Budberg, 2010).

3.2. Surgical management

CrCL rupture leads to instability of the joint which, in turn, leads to progression of osteoarthritis. Hence, some authors consider conservative management an inappropriate choice (Paatsama, 1952; Arnoczky, 1988). If lameness persists after conservative treatment, surgical

stabilization of the stifle joint should be strongly recommended. In larger breeds, early surgical management is recommended in order to minimize the development of osteoarthritis (Pond, 1972; Arnoczky, 1980). Surgery also allows assessment of the menisci and treatment of such condition in case of meniscal injury (Franklin, Gilley & Palmer, 2010).

If a dog presents with bilateral CrCL rupture, the limb causing the worst lameness should be assessed first and the second surgery should take place in 6 to 12 weeks later, if periarticular fibrosis has not stabilized the joint yet, since single-stage bilateral surgeries are associated with an increased risk of complications compared to unilateral surgery (Kiefer, Langenbach, Boim, Gordon & Marcellin-Little, 2015; Boudrieau & Kowaleski, 2009; Kergosien et al., 2004).

There are several techniques used to manage CrCL rupture in dogs, but there is not a single one that is considered entirely satisfactory (Vasseur, 2003). In general, surgical techniques can be divided into intra-articular, extracapsular and tibial osteotomies.

3.2.1. Intra-articular or intracapsular techniques

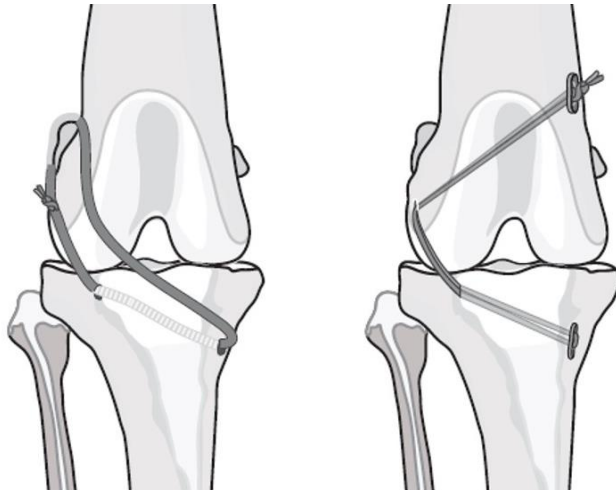
Intra-articular techniques provide stabilization of the stifle by repairing or replacing the ligament with a graft. Currently, primary repair of the CrCL is rarely attempted due to the technical limitations intrinsic to pre-existing CrCL degeneration and poor regenerative capacities of the damaged ligament (O'donoghue, Rockwood, Frank, Jack & Kenyon, 1966). Intracapsular techniques are technically more demanding than the extracapsular stabilization techniques. Many techniques have been developed for replacing the CrCL using autografts, allografts and prosthetics (Manley, 2010). Paatsama (1952) described the first surgical procedure for treatment of the CrCL rupture, in which the normal CrCL attachments and orientation were simulated by placement of an intra-articular fascia lata autograft through bone tunnels drilled on the femur and tibia (Paatsama, 1988). Later, Arnoczky et al. (1979) described the "over-the-top" procedure, which involves a graft of the medial third of the straight patellar ligament passing through the stifle along the original CrCL's path. The free end of the graft is then passed over the top of the lateral femoral condyle and sutured to the tissues on the lateral femoral condyle (Arnoczky, Tarvin & Marshall, 1982). Other intra-articular techniques were described such as modifications of these two techniques (Dickinson & Nunamaker, 1977; Hulse, Michaelson, Johnson & Abdelbaki, 1980). In such procedures, the anatomic configuration of the CrCL and its attachments to bone make its replication hardly accurate, which leads to excessive tension during flexion of the stifle resulting in early breakdown of the replaced ligament due to failure to recreate the mechanical environment of the CrCL (Manley,

2010). Consequently, these techniques have shown worse outcomes than extracapsular or dynamic stabilization techniques (Conzemius et al., 2005).

3.2.2. Extracapsular techniques

Extracapsular stabilization of the stifle joint consists of using a biological or synthetic material with femoral and tibial fixation points to passively resist cranial drawer, internal rotation and hyperextension, temporarily, while periarticular fibrosis develops, to then provide function and stability of the stifle in the long-term. These procedures are relatively simple to perform, not requiring highly technical equipment with low related costs, and are associated with good outcomes, in terms of safety and efficiency, which have been reported to be comparable to the outcomes of tibial osteotomies for management of the CrCL disease (Cook, 2010; Cook, Luther, Beetem, Karnes & Cook, 2010; Conzemius et al., 2005; Lazar, Berry, deHaan, Peck & Correa, 2005; Millis, Durant, Headrick & Weigel, 2008; Au et al., 2009).

Figure 6: Illustrations of lateral femorotibial suture (Left) and TightRope (Right) methods for extracapsular stabilization in the dog. (Adapted from: Muir, P. Structure and Function, Advances in Canine Cranial Cruciate Ligament, 1st ed., 2010, p. 166. Wiley-Blackwell)



DeAngelis and Lau (1970) described the lateral suture stabilization technique, which consists of placement of sutures from around the fabella to the point of insertion of the patellar ligament. The majority use synthetical implants placed on the lateral side of the stifle. However, various materials have been used for these procedures, including multifilament braided materials, such as polyester or fiberwire, which have better stiffness, creep, load-to-failure and knot security than monofilament materials, such as nylon or polypropylene, which, in turn, are less susceptible for infection, tissue reaction or sinus formation and allow crimp fastening. Joint stability is more effectively maintained by crimped loops when compared to knotted loops

(Vianna & Roe, 2006). A modification of the technique described by DeAngelis and Lau, named the lateral fabellotibial suture, is widely used in veterinary medicine, representing one of the most common extracapsular procedures performed (DeAngelis & Lau, 1970; Cook, 2010; Kowaleski et al., 2012). This procedure stabilizes the stifle by placing a heavy gauge suture material around the lateral fabella and through a tunnel in the proximal tibial metaphysis (Kowaleski et al., 2012) and relies on periarticular fibrosis to provide a long-term restraint to cranial translation of the tibia. A crimp clamp system has been shown to ease the tightening of heavy nylon material and enhance the biomechanical properties of the repair (Anderson et al., 1998). However, the materials used stretch or break at some point. If that occurs before the healing process is finished, instability correction fails. Recently, a modification of the lateral fabellotibial suture, the TightRope® (Arthrex Vet Systems, Naples, FL) procedure, has been described, using a strong type of suture and fixation to bone, and has been associated with better outcomes in strength and stiffness, as well as, less displacement during cyclic loading (Cook et al., 2010). Reported complications associated with extracapsular techniques include incorrect implant placement (in tension or location), postoperative implant loosening, postoperative meniscal tears and infection. Casale & McCarthy (2009) reported a complication rate of 17.6% associated with lateral fabellar suture repair in a study including 363 cases and 7.2% of limbs required additional surgery to treat a complication. In the same study high body weight (more than 35 kg) and young age of dog (younger than 5 years of age) at the time of surgery were factors that associated significantly with a higher rate of complications.

3.2.3. Tibial Plateau Levelling Techniques

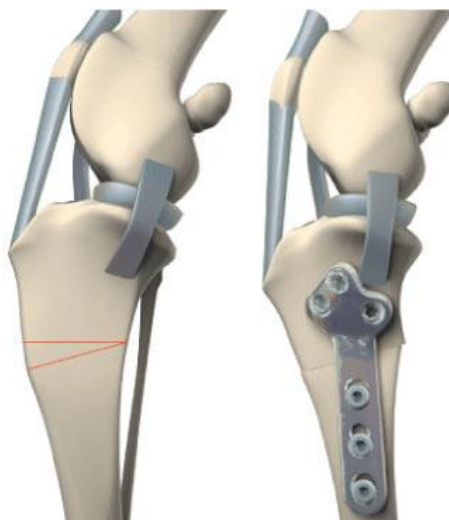
Despite the reported good limb function in most of the dogs that have had extra or intracapsular procedures for correction of CrCL rupture, these methods are generally far from having optimal long-term outcomes because they are not reliable at maintaining stifle stability, reducing progression of osteoarthritis nor preventing late meniscal injuries (Gambardella, Wallace & Cassidy, 1981; Chauvet, Johnson, Pijanowski, Homco & Smith, 1996; Vasseur & Berry, 1992). In 1984 a new concept was born when Slocum described the cranial tibial wedge ostectomy (CWO). This new concept is based on dynamic stabilization of the CrCL-deficient stifle by changing bone geometry, with no need for passive restraint against laxity. Therefore, tibial osteotomies make no attempt at restoring anatomic stability; instead they provide functional stifle stability only during weight bearing. CWO intends to eliminate cranial subluxation of the tibia during weight-bearing by reducing the tibial plateau slope. Other several procedures based

on the same theory were then described, particularly the tibial plateau levelling osteotomy (TPLO), which has gained in popularity since introduced in 1993 (Corr, 2009; Aragon & Budsberg, 2005).

3.2.3.1. Closing Wedge Osteotomy

The cranial tibial closing wedge osteotomy (CWO) was first described in 1984, by Slocum, for treatment of CrCL rupture in dogs, and it consisted of removing a wedge of bone, by performing an osteotomy, at the proximal third of the tibia; with the wedge angles ranging from 18° to 30° as the method used to determine the wedge angle for individual cases was not specified, with the objective of reducing the TPA (Slocum & Devine, 1984). Currently, CWO surgery is performed as a definitive stabilization procedure that aims to reduce the TPA to about 5° , in order to provide stifle stability and eliminate cranial tibial translation during the stance phase of the gait cycle, by neutralizing the cranial tibial thrust force. Thus, the need for a CrCL as a restraint to the cranial tibial thrust is eliminated. This is achieved by performing two osteotomies in the proximal third of the tibia, so that a wedge of bone can be removed, followed by reduction with apposition of both margins of the osteotomised site and fixation with a plate and screws (Dejardin, 2003).

Figure 7: Illustrations of the Closing Wedge Osteotomy Procedure: the angle of the wedge of bone to be removed is delineated (Left) and then two osteotomies are performed. The fracture is reduced and fixation is performed with the placement of a plate and screws (Right). (From: Surgivet (2014). *Cruciate repairs in dogs*. Accessed June 2016, in <http://www.surgivet.co.uk/cruciate-repairs-in-dogs.html>)



The osteotomy should be performed as most proximally as possible, immediately distal to the tibial crest, while ensuring that both fragments of bone are long enough for placement of, at

least, three screws in each (Bailey, Smith & Black, 2007). The caudal edge of the tibia can be left intact for stability. Some surgeons will require an assistant to hold the two fragments of the tibia together while the plate and screws are being placed, whereas others opt to place an orthopaedic wire through drilled holes, positioned cranially, immediately proximal and distal to the osteotomy surfaces and tightening it to compress the wedge shaped gap in between. The plate(s) have to be contoured before fixation for a more accurate reduction of the osteotomy site and is then placed on the medial surface of the tibia as adjustments are made to ensure the perfect alignment of the two bone fragments for an accurate reduction before placement of the screws. It is recommended to place one of the screws with the limb in a load position to provide compression of the osteotomy surfaces (Dejardin, 2003) Size and number of plates needed depend on the patient's body weight.

The angle of the osteotomy is determined based on the preoperative TPA measured on radiographic examination. For measurement of the TPA a mediolateral radiograph is required and a correct positioning is very important. Stifle and tarsus have to be included in the radiograph and the femoral condyles should exactly overlap each other. Sandbags or foam wedges can be used if necessary. The beam should be centred over the stifle (Dejardin, 2003). It has been shown that limb position affects radiographic TPA measurement. Cranial and proximal positioning of the limb relative to the X-ray beam results in TPA overestimation. In contrast, caudal and distal positioning results in underestimation of the TPA (Reif et al. 2004). The TPA measurement follows four steps. The first three consist of drawing the following lines on the radiograph:

- Functional tibial axis line, which passes through the centre of the talus and the centre of the intercondylar eminences
- Medial tibial plateau line, connecting the cranial aspect of the medial tibial plateau to the caudal aspect of the medial tibial plateau
- Reference line, which is a line perpendicular to the functional tibial axis line

Finally, the TPA can be measured as the angle formed by the medial tibial plateau line and the reference line (Dejardin, 2003). TPA readings obtained from different readers can vary up to ± 4.8 degrees and intraobserver variability can reach ± 3.4 degrees (Caylor, Zumpano, Evans & Moore, 2001).

As the desired postoperative TPA is around 5° , the angle of the osteotomy is determined by the preoperative TPA minus 5° (for example, if the preoperative TPA is 30° , the angle of the wedge to be removed will be 25°) (Dejardin, 2003). However, some biomechanical studies suggest that the angle of the wedge to be removed has to be the same as the preoperative TPA, in order

to achieve a postoperative TPA of 5° (Apelt, Pozzi, Marcellin-Little & Kowaleski, 2005). One would think this would originate a postoperative TPA of 0° , which, in practice, does not verify due to the deviation of the functional tibial axis produced by the CWO. After the procedure, the intercondylar eminences are cranially deviated, resulting in a deviated functional tibial axis (Bailey et al., 2007; Kowaleski & McCarthy, 2004). The difficulty of achieving accurately the desired postoperative TPA of 5° is most likely owed to the variability of size and osteotomy positioning along with the deviation of the functional tibial axis (Bailey et al., 2007). With the purpose of overcoming this, the osteotomy should be done as proximal as possible, the cranial cortices should be aligned and 2° - 3° may be added to the size of the wedge to be removed (Bailey et al., 2007).

Clinical bone union usually takes about 6 weeks to occur (Dejardin, 2003). Restriction of physical activity is mandatory during the healing process and gradual increase in exercise should be attained. Physiotherapy is usually recommended in order to enhance recovery, particularly hydrotherapy, which may be initiated 10 to 14 days after surgery, once the surgical wound has healed (Caldwell, 2015). The cranial drawer sign will remain positive after surgery since there is no CrCL. However, the tibial compression test will usually be absent by three months postoperatively (Slocum & Devine, 1984).

Slocum reported a 79% excellent results in 19 dogs, with the major complications being tibial fractures and screw loosening, whereas a rate of 94% good to excellent results and 8.4% complication rate requiring second surgical intervention were reported in a combined TPLO and CWO series in 1993 (Slocum & Devine 1984). In a series of 122 CWO cases were presented, revealing 86% of good to excellent return to function (Watt, Sommerlad & Robins, 2000). Holsworth (2004) referred a complication rate of 11.9% of 101 CWO procedures requiring second surgical intervention. Corr and Brown (2007) reported 92% “good” or “excellent” outcomes with either CWO or TPLO techniques and determined there was not a significant difference in outcome between dogs that had TPLO or those that had CWO procedure. Moreover, all dogs (19 dogs that underwent TPLO and 18 that underwent CWO) revealed a rapid return to weight bearing after surgery and complication rates did not differ between the two groups. However, in this study, complications associated with CWO were more likely to require surgical management (Corr & Brown, 2007).

This technique has been reported to have a faster return to weight-bearing than other surgical techniques (Watt et al., 2000).

A study in which kinematic gait was analysed, in ten adult beagles that were assigned to TPLO (five dogs) and CWO (five dogs), showed that dogs which underwent CWO procedure for repair of a CrCL rupture were more likely to have significantly hyperextended gait patterns

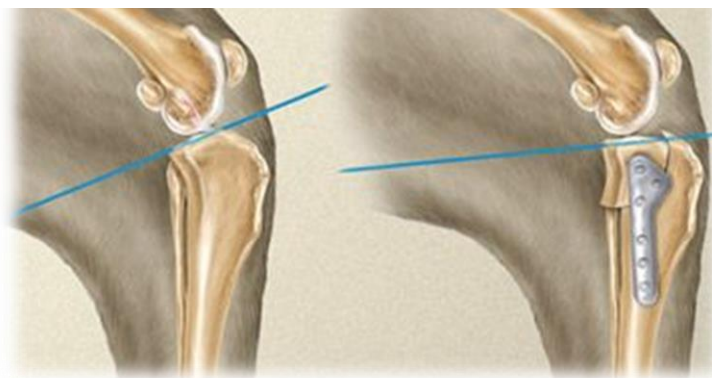during the swing phase of the gait cycle, while trotting, than those that underwent TPLO procedure. CWO surgery changes stifle and tibiotarsal joint angles compared with preoperative values. However, during stance phase, dogs that underwent CWO had normal joint angles and did not differ from those that underwent TPLO procedure. Despite the differences observed during the swing phase of the gait, it is likely to be no clinical difference in these dogs, notwithstanding which surgical technique is performed (Lee, Kim, Kim & Choi, 2007).

Data on complication rates associated with CWO is much scarce than that of TPLO. Retrospective studies show relatively high complication rates of 31-36%, whereas reoperation rates of 12-18% have been reported with CWO technique in medium and large dogs (Kuan, Smith & Black, 2009).

3.2.3.2. Tibial Plateau Levelling Osteotomy

Tibial plateau levelling osteotomy (TPLO) is another procedure which results only in dynamic stifle stability. For this reason and because TPLO does not attempt to restore the passive constraint of the CrCL, cranial tibial translation can still be elicited manually after surgery (Slocum & Slocum, 1998). Stabilization of the stifle during weight-bearing is attained by decreasing cranial tibial thrust, which leads to a functional stabilisation by enhancing the effectiveness of the hamstrings and biceps femoris muscles (Slocum & Slocum, 1998). A reduced TPA prevents cranial thrust by limiting the shear force generated by compression of the stifle during weight-bearing (Slocum & Slocum, 1993; Slocum & Devine, 1983).

Figure 8: Illustrations of Tibial Plateau Levelling Osteotomy Procedure: the blue line shows the change in the tibial plateau slope. (From: Laurie O'Keefe (2015), Veterinary. Accessed June 2016, in <http://laurieokeefe.com/veterinary/#gallery/1008/74>)



Similarly to the CWO procedure, the target in TPLO technique is to achieve a TPA of 5°. However, in this case, the target TPA is conceivable by a radial osteotomy of the proximal tibia

and rotation of the bone segment, with subsequent placement of a TPLO plate and screws for fixation, according to the principles of internal fixation (Kowaleski et al., 2012). Conventional screws or locking screws can be used for fixation of the plate. The use of locking screws has shown an increased stabilization of TPA during bone healing and improved radiographic evidence of osteotomy healing (Conkling, Fagin & Daye, 2009). The magnitude of rotation necessary for each individual case is based on the preoperative patient's TPA, measured on radiography. The correlation between preoperative planned magnitude of rotation and postoperative TPA is good (Windolf et al., 2008). Nevertheless, it is a challenging technique to perform and requires great accuracy when executing the osteotomy and the rotation to precisely obtain the desired postoperative TPA. The osteotomy should be centred on the proximal tibial long axis point dividing the intercondylar tubercles. If positioned distally, a greater TPA than what is expected may result (Kowaleski, Apelt, Mattoon & Litsky, 2005).

It is of major importance to assess intra-articular structures for appropriate treatment of other abnormalities such as meniscal injuries, which can be associated with CrCL rupture.

Early intensive physiotherapy has proved to be beneficial and should be considered as part of the postoperative management to induce functional improvement in ROM of the stifle joint, prevent muscle atrophy and build muscle mass and strength. The intensive program should be closely monitored by a physiotherapist (Monk, Preston & McGowan, 2006).

TPLO technique is associated with high long-term success rates and it is more likely to be associated with full function outcomes when compared with TTA surgery (Christopher, Beetem & Cook, 2013). In a randomized, blinded, controlled clinical trial, owners, whose dogs had undergone surgical treatment for CrCL repair, ranked their satisfaction 1 year after surgery as a minimum score of 9 out of 10 in 95% of TPLOs (Gordon-Evans et al., 2013).

Complications associated with TPLO procedure have been well documented in the veterinary literature but rate and type of complications vary significantly between studies. Complications include subsequent meniscal injury, implant failure, infection, incisional complications such as inflammation, drainage, swelling, seroma and infection, tibial tuberosity fracture/avulsion, patellar tendonitis, medial patellar luxation and intra-articular screw placement (Fitzpatrick & Solano, 2010; Garnett & Daye, 2014; Gordon-Evans et al., 2013; Nelson et al., 2013; Oxley, Gemmill & Renwick, 2013; Gatineau, Dupuis, Planté & Moreau, 2011). Incisional complications and infections represent the majority of complications but most of them don't require surgical intervention. The most common major complications, which require second surgical treatment, include subsequent meniscal tear, osteomyelitis, tibial fractures and non-union. In a study involving 297 TPLO procedures the complication rate reported was 28% (Pacchiana, Morris, Gillings, Jessen & Lipowitz, 2003). Another study reported a complication

rate of 20.6% of all 253 TPLOs analysed with approximately 25% of the 193 dogs being affected, with a higher incidence of complications when bilateral TPLOs were performed during a single anaesthetic episode (Priddy, Tomlinson & Dodam, 2003). Holsworth (2004) referred a complication rate of 4.5% in 156 TPLO procedures requiring second surgical treatment. In 2006 an overall complication rate of 18.8% was reported in a study of 696 TPLO procedures (Stauffer, Tuttle & Elkins, 2006). However, the most recently reported retrospective studies reveal a much lower rate of TPLO complications, varying from 9.7% to 14.8% (Gatineau et al., 2011; Fitzpatrick & Solano, 2010; Coletti, Anderson, Gorse & Madsen, 2014). Factors such as increased age and body weight, breed, complete preoperative CrCL tear, steep TPA, thin craniocaudal crest and surgeon's experience may predispose to complications (Pacchiana et al., 2003; Bergh, Rajala-Schultz & Johnson, 2008; Tuttle & Manley, 2009; Fitzpatrick & Solano, 2010; Gatineau et al., 2011; Taylor, Langenbach & Marcellin-Little, 2011; Bergh & Peirone, 2012). Bilateral TPLOs performed during a single anaesthetic episode were initially discouraged because of their high complication rate of 40% (Priddy et al., 2003). Preventative measures, such as the use of locking implants specifically designed for TPLO procedures, which reduce the technical difficulty of the technique and also, adjustment in the postoperative management of patients, in order to avoid contamination and provide a rapid return to function without premature loading of the limb, have been developed in an attempt to reduce complication occurrence (Griffon, 2016).

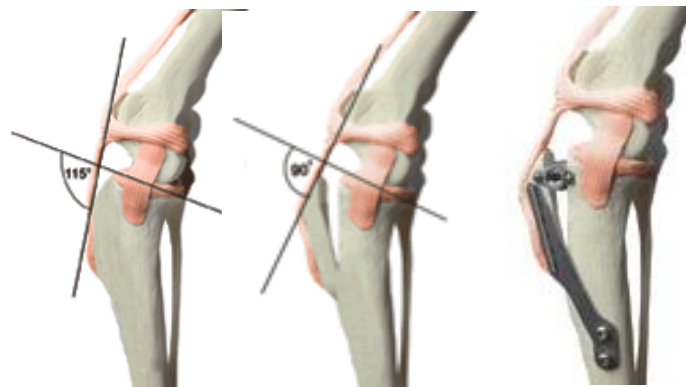
3.2.4. Tibial Tuberosity Advancement

Tibial tuberosity advancement (TTA) also attempts to achieve dynamic stabilization of the stifle. In this procedure, craniocaudal stability is achieved by changing the relative alignment of the patellar tendon to the tibial plateau. A frontal plane osteotomy of the tibial crest advances the patellar tendon perpendicular to the tibial plateau, neutralizing cranial tibial thrust. This technique was first described by Maquet (1976) and it is based on a human mechanic model of the knee forces acting on the joint during weight-bearing.

There was evidence that a variable tibiofemoral shear force was present in the knee. This force was directed either anteriorly during extension or posteriorly during flexion, subsequently depending on the patellar tendon angle (PTA), which corresponds to the angle between the patellar tendon and the tibial plateau (Nisell, Németh & Ohlsén, 1986). In full extension the PTA is bigger than 90° and in full flexion is smaller than 90° . On the point where the PTA is 90° , the “crossover” point, there is no cranial nor caudal tibiofemoral shear force present. The

TTA alters the geometry of the proximal tibia so that the PTA is maintained under 90° throughout weight-bearing. This way, TTA neutralizes cranial tibiofemoral shear force in a stifle with CrCL rupture (Maquet, 1976; Nisell et al., 1986; Montavon, Damur & Tepic, 2002; Tepic, Damur & Montavon, 2002). Stifle stability is achieved by advancing the tibial tuberosity until the PTA reaches 90° (Tepic et al., 2002).

Figure 9: Illustrations of the Tibial Plateau levelling osteotomy: the PTA is measured and the tibial tuberosity is advanced and fixed aiming a final PTA of 90° . (Adapted from: Allegheny Veterinary Associates (2007). TTA: Tibial Tuberosity Advancement, Accessed June 2016, in <http://www.alleghenyvet.com/tta-tibial-tuberosity-advancement/>



TTA procedure is considered a method of CrCL repair with good to excellent functional outcome, which can be successfully used to obtain dynamic stability of the stifle joint in dogs. In a retrospective study, 84% of owners, whose dogs had undergone TTA procedure, stated that they would be willing to repeat the procedure (Steinberg, Prata, Palazzini & Brown, 2011). Complications associated with this technique have been reported, most recently, in a retrospective study of 501 TTA procedures, with an overall complication rate of 19% (Wolf, Scavelli, Hoelzler, Fulcher & Bastian, 2012). The authors consider such complication rate comparable to those reported for TPLO procedures and lower than rates previously reported for TTAs. In 2007 a retrospective study of 101 dogs that underwent TTA reported an overall complication rate of 31.5%, 12.3% being major and 19.3% minor complications (Lafaver, Miller, Stubbs, Taylor & Boudrieau, 2007). Complications associated with TTA procedure include subsequent meniscal tear, with a reported incidence of 27% (Christopher et al., 2013); tibial fractures involving the tuberosity or, less commonly, the diaphysis, with an overall incidence of 4 to 5% (Wolf et al., 2012; Calvo et al., 2014); implant failure, reported in about 2% of cases (Wolf et al., 2012); infection; lick granuloma; incisional trauma and medial patellar luxation, reported in an average of 3.2% of cases (Hirshenson et al., 2012; Steinberg et al., 2011; Yeadon, Fitzpatrick & Kowaleski, 2011; Lafaver et al., 2007). Similarly to TPLOs,

incisional complications, such as infection and inflammation, were the most commonly reported complications, with an incidence of approximately 35%, generally resolving with medical treatment (Griffon, 2016).

4. OVERVIEW OF COMPLICATIONS ASSOCIATED WITH SURGICAL MANAGEMENT OF THE CRANIAL CRUCIATE LIGAMENT RUPTURE

4.1. Degenerative joint disease

Degenerative joint disease (DJD) is the result of mechanical and biologic events that disrupt the regular balance of degradation and synthesis of articular cartilage and subchondral bone, affecting the chondrocytes and surrounding matrix, leading to morphologic, biochemical, molecular and biomechanical changes. DJD is responsible for causing pain, decreasing range of motion, creating crepitus and inflammation. DJD is often already present in cases of CrCL disease at the time of surgical treatment. However, iatrogenic articular damage, which means injury to the cartilage caused by a diagnostic or therapeutic procedure, may cause DJD in cases that showed no alterations previously or can aggravate the condition in cases that had already degenerative joint changes. Despite being a common complication, iatrogenic articular damage is rarely reported (Klein & Kurze, 1986; Byrd, 2000). Exposure of subchondral bone can be identified by direct visualisation and absence of remodelling as well as fresh lesion edges support the diagnosis of acute damage. It may result from direct trauma to the articular surface, which may occur during arthrotomy or arthroscopy, or secondary to penetration of an implant (usually, a screw) in the subchondral bone or in the deeper layer of the cartilage, compromising the tissue biomechanics. Initial studies on TPLO reported 1% or fewer cases of intra-articular placement of screws or jig pins (Pacchiana et al., 2003; Priddy et al., 2003). Intra-articular placement of surgical implants, implant migration, inadequate use of instrumentation during intra-articular surgery, meniscectomy and meniscal release (Luther, Cook & Cook, 2009) are factors that contribute to DJD. CrCL disease is a predisposing cause for DJD and, even though, surgery acts on the cause, it cannot correct secondary degenerative changes, therefore, allowing the breakdown cycle of articular cartilage. Moreover, progression of DJD is an expected outcome after most intra-articular surgeries, being reported to occur in 40% to 76% of dogs after TPLO (Lineberger et al., 2005; Boyd, Miller, Etue & Monteith, 2007; Hurley, Hammer & Shott, 2007), 55% in cases of TTA (Morgan et al., 2010) and in 100% of cases after intracapsular techniques (Boyd et al., 2007).

Alongside with meniscal surgery, failure of achieving joint stability by either incorrect reduction of the osteotomy or implant failure (eg. loosening screws) can alter load distribution throughout the joint, leading to progression of DJD. In cases of intra-articular implant placement the implant should be immediately removed to avoid postoperative pain and progression of DJD. Long-term medical management should be considered in all cases and include weight and exercise management, use of nutraceuticals, rehabilitation and NSAID therapy. Postoperative immobilization leads to decreased synovial fluid production, cartilage stiffness and thickness that result in ulcerative lesions over opposing surfaces of articular cartilages, therefore, postoperative rehabilitation is becoming standard of care after joint surgery (Marsolais, Dvorak & Conzemius, 2002).

4.2. Infection

Surgical wound infection is the most common cause of postoperative morbidity, with rates of 5.1% (Vasseur, Levy, Dowd & Eliot, 1988) to 5.8% (Eugster, Schawalder, Gaschen & Boerlin, 2004) in small animals. Risk factors include those that are patient-related, such as age, body weight (Eugster et al. 2004), nutritional status or altered immune status (Mangram, Horan, Pearson, Silver & Jarvis, 1999; Ata, Lee, Bestle, Desemone & Stain, 2010; Moucha, Clyburn & Evans, 2011) and those which are operation-related, such as duration of surgical scrub, preoperative clipping and skin preparation (Brown, Conzemius, Shofer & Swann, 1997), duration of surgery (Vasseur et al., 1988; Brown et al. 1997; Eugster et al., 2004) and anesthesia (Nicholson, Beal & Shofer, 2002; Eugster et al., 2004; Owen et al. 2009), antimicrobial prophylaxis, operating room ventilation, sterilization of instruments, foreign material in the surgical site or surgical technique (Laitinen-Vapaavuori, 2016). In a recent meta-analysis, it was concluded that preoperative cleansing with chlorhexidine is superior to povidone-iodine in reducing postoperative wound infections after clean-contaminated surgery (Noorani, Rabey, Walsh & Davies, 2010). Diagnosis is based on clinical signs, such as presence of purulent discharge, redness, pain, swelling and heat, and possible positive bacterial culture from infection site. If only redness, swelling or heat is present, one has to differentiate it from the normal inflammatory response expected during early wound healing, which generally subside within 24 to 48 hours post-surgery (Laitinen-Vapaavuori, 2016). These signs can also be accompanied by systemic signs, such as fever, tachypnea and leukocytosis with a left shift. When the infection involves the bone, radiographic examination may be warranted and signs of inflammation of the bone (osteomyelitis) can be identified. Surgical drainage or wound

debridement may be required depending on the extent of tissue involvement, associated to appropriate antimicrobial therapy, which should, preferably, be based on bacterial culture results, and pain relief. Superficial infections that only involve the skin and subcutaneous tissues have good prognosis, though it may prolong recovery time. Infections involving deep tissues or bone can seriously affect the outcome of surgery, causing greater discomfort to the patient, increasing costs and prolonging significantly recovery (Laitinen-Vapaavuori, 2016). Therefore, osteomyelitis represents one of the most challenging complications after orthopedic surgery. In 2003 a retrospective study of 253 TPLOs reported osteomyelitis as the single most common complication (Priddy et al., 2003). Later studies revealed lower rates, ranging from 3% to 10% (Frey, Hoelzler, Scavelli, Fulcher & Bastian, 2010; Bergh & Peirone 2012; Etter, Regetly, Bennett & Schaeffer, 2013). The organisms most commonly isolated include gram-positive organisms, particularly *Staphylococcus spp.*, which was isolated in 14 cases in a study of 21 TPLO plate removals due to postoperative infection (Gallagher & Mertens 2012). Another study reported 13 *Staphylococcus pseudointermedius* isolates of 15 infected TPLOs, 4 of which were methicillin resistant (Nazarali, 2013). Use of skin staples has been identified as a factor predisposing to surgical wound infection, having nearly doubled (factor 1.9) the risk of infection or inflammation after staple closure in 902 CrCL repairs (Frey et al., 2010). Soft tissue swelling associated to osteomyelitis may appear radiographically within 24 to 48 hours but bony changes take normally 10 to 14 days. Yet, definitive diagnosis and antibiotherapy should be based on culture and sensitivity test from deep aspiration or tissue biopsy. Treatment usually requires surgical debridement, allowing also assessment of the underlying factors that caused the infection, such as loose metallic implants or presence of necrotic tissue, and long-term (minimum 6 weeks) systemic antibiotherapy. Prophylactic antibiotherapy is justified by duration of surgery, placement of implants and pre-existing compromise of trauma patients. A study of 808 dogs that underwent TPLO procedure showed that dogs which do not receive postoperative antibiotherapy are four times more likely to develop surgical site infection than dogs that received postoperative antibiotics (Frey et al., 2010), which was then supported by another study of 1000 TPLOs, in which the probability of developing postoperative infections of a dog that received postoperative antibiotics was half the odds of a dog that did not receive such treatment (Fitzpatrick & Solano, 2010). Modifications to biomaterial surfaces of implants at an atomic level (by polishing and coating) may improve fibroblast and osteoblast cells attachment and proliferation, whereas minimizing bacterial adhesion, therefore preventing implant-related osteomyelitis (Gristina, 1987).

4.3. Delayed bone healing

Adult dogs generally have radiographic evidence of bone bridging fracture line by 12 weeks and immature dogs by 6 weeks. When bone healing is not as quick as expected, based on biologic, mechanical and clinical factors, it is considered delayed union. The anticipated fracture healing rate takes into consideration the location of the fracture, the nature of the traumatic injury, the animal's systemic state, the fixation of the fracture and postoperative management (Hayda, Brighton & Esterhai, 1998). Factors that contribute for the occurrence of this complication include systemic illness, compromised vascular supply, unstable implants, extremely rigid fixation, infection, poor postoperative management and pharmacologic factors such as use of corticosteroids and NSAIDs. Long-term administration of carprofen seemed to inhibit bone healing in tibial osteotomies in dogs (Ochi et al., 2011). Radiography is the standard method to evaluate bone healing (Axelrad & Einhorn, 2011), although weight bearing and pain on palpation are important clinical signs. In general, fractures that are not healed by 12 to 16 weeks or that have evidence of progressive healing but with doubt relatively to outcome, are diagnosed as delayed unions. Unstable fixation can lead to non-union and, in that case, implants should be replaced and a bone graft is recommended, followed by radiographic examination in 6-week intervals. In cases where implants show no evidence of impending failure and there is evidence of bone healing, conservative care is the option, consisting of continued confinement and serial evaluations. If there is minimal progression of healing, a cancellous bone autograft or allograft with demineralized bone matrix can be inserted surgically to promote healing (Hoffer, Griffon, Schaeffer, Johnson & Thomas, 2008).

4.4. Subsequent meniscal disease

Meniscal lesions that were not diagnosed during the first approach to CrCL treatment and were then detected postoperatively are considered subsequent meniscal injuries. Its pathogenesis can generally be attributed to residual joint instability and abnormal distribution of loads across the joint. It is one of the most common complications found after CrCL repair, with an approximately incidence of 3% to 6%, with great variations amongst reports. The medial meniscus is most frequently affected and bucket handle tears are the lesions most commonly identified, representing approximately 76% of cases reported by Case et al. (2008), whereas lesions such as frayed caudal horn tears of the medial meniscus and longitudinal tears of the lateral meniscus were only diagnosed in approximately 21% and 3%, respectively, of cases reported in the same study, in which 26 dogs (29 stifles) had second arthroscopic examination

due to lameness following CrCL repair surgery. Subsequent meniscal disease should be suspected in dogs that had previous surgery for correction of CrCL failure presented for persistent lameness, acute onset of lameness or failure to improve to predictable levels of function. Dogs with pain upon flexion of the stifle are 4.3 times more likely to have medial meniscal disease and detection of an audible meniscal click increased the likelihood of the disease by a factor of 11.3 (Dillon et al., 2014). A definite diagnosis is achieved, preferably, by arthroscopy or by direct inspection via arthrotomy. Partial meniscectomy, hemi-meniscectomy or complete meniscectomy, according to the grade of meniscal damage, can be performed either via arthroscopy or arthrotomy improving or resolving lameness in about 95% of cases (Case et al., 2008). Progression of DJD is expected in such cases and so, medical management should be considered for this condition after surgery. To prevent subsequent meniscal injuries, recommendations are to improve the detection of pre-existing lesions at first assessment of CrCL disease, which is best achieved via arthroscopy (Plesman et al., 2013; Ritzo et al., 2014). Medial meniscal release is a preventative measure which has been developed in an attempt to overcome this problem. It has been introduced to allow the medial meniscus to move away from the crush exerted by the medial femoral condyle during cranial translation of the tibia. In a clinical study of 163 dogs with CrCL disease this procedure showed to be effective at decreasing the risk of subsequent meniscal disease (Ritzo et al., 2014). Currently, caudal meniscal release via transection of the caudal meniscotibial ligament is preferred over a radial release (Griffon, 2016). However, the efficacy of meniscal release is still a controversial topic as it has also been associated to predispose to progression of OA (Pozzi et al., 2008).

4.5. Osteosarcoma

Primary tumours of bone may arise at a previous fracture site, possibly secondary to the original trauma or placement of implants, although plate fixation is most commonly associated with this condition. Despite osteosarcomas being the tumours most commonly reported, undifferentiated sarcomas, fibrosarcomas and other tumour types have also been described. Some studies report sarcomas of the proximal tibia in dogs after TPLO (Boudrieau, McCarthy & Sisson, 2005; Straw, 2005; Harasen & Simko, 2008; Atherton & Arthurs, 2012; Selmic et al., 2014). In a study of 1135 cases of appendicular osteosarcoma, 17% were at sites of previous TPLO surgeries. However, dogs that have bilateral procedures are 8.4 times more likely to develop a tumour (Sartor, Selmic, Withrow & Ryan, 2013). The fact that osteosarcomas spontaneously develop in the proximal tibia makes it harder to establish a correlation between TPLO and

sarcomas. Even though, it has been proposed that corrosion of stainless steel implants could increase osteolytic activity in adjacent bone and chronic synovitis, potentially contributing to neoplasia. This would justify explantation of TPLO plates after clinical union of the osteotomy. Treatment options, most commonly, include amputation with or without chemotherapy. Selmic et al. (2013) reported a median survival time of 313 days after limb amputation and adjuvant chemotherapy, in ten out of 29 dogs diagnosed with proximal tibial osteosarcoma at least 1 year after TPLO.

4.6. Implant failure

Implant failure results from implant loosening or breakage, compromising stabilization of the osteotomy and subsequent bone healing (Griffon, 2016). Use of non-locking screws or failure to obtain bicortical fixation, excessive postoperative exercise, infection, excessive micromotion at the osteotomy site, concurrent fibular head fractures and delayed bone healing are factors that may contribute to implant failure (Griffon, 2016). Clinical signs vary according to the type of implant failure and can be absent in certain cases, such as those of loosening of single screw that is sometimes found at follow-up radiographies, or can be obvious and sudden with non-weight-bearing lameness and crepitus on palpation (Griffon, 2016). The diagnosis is confirmed through radiographic examination and signs may include radiolucency around the implant, implant migration, loss of reduction of the osteotomy, delayed healing and bone fracture. In cases where implant loosening is an incidental finding, conservative management associated with rest may be considered if progression is the expected and further assessment should be carried out if stability is questionable or if bone healing is delayed (Griffon, 2016). Other cases require immediate surgical revision, often with implant replacement, after which procedure the prognosis is generally good, although bone healing may delay. Mostly, implant failure results from inadequate technique for plate contouring or failure to obtain bicortical screw fixation (Griffon, 2016).

4.7. Bone fractures

Bone fractures secondary to TPLO may occur in the fibula, tibia and tibial tuberosity. Tibial tuberosity avulsion fractures have been reported in 4% of 213 TPLOs in a retrospective study (Bergh et al., 2008). Incidence of fibular fractures vary amongst studies, having been reported 5.4% in a study of 168 TPLOs (Tuttle & Manley, 2009) and 15% in other study of 355 TPLOs

(Taylor et al., 2011). Both fibular and tibial tuberosity fractures are generally diagnosed on follow-up radiographs. Fibular fractures are treated conservatively unless they are associated with implant failure. Tibial fractures are not common but mean major complications after TPLO, inducing non-weight bearing lameness, and they are normally concomitant with implant failure (Griffon, 2016).

5. OBJECTIVES

The objective of this study was to describe the surgical technique and complications of closing wedge ostectomy for treatment of CrCL disease in dogs, performed by one veterinary surgeon at Kingston Veterinary Group over the last 9 years.

II. MATERIALS AND METHODS

1. Inclusion criteria

Medical records of 108 dogs (145 stifles) that underwent a standard CWO for CrCL rupture at Kingston Veterinary Group in Hull, performed by Dr. David Robinson, between August 2007 and November 2015 with more or at least 6 months follow-up were reviewed. A dog was eligible for inclusion when CWO surgery was performed after diagnosis of CrCL rupture by examination under general anaesthesia and through radiographic examination and when the medical record included information regarding signalment, details of surgical procedure, history of complications intra and postoperatively and follow-up examinations.

2. Signalment

Data obtained from medical records included breed, sex, age, body weight, affected limb, stifle radiograph findings, preoperative TPA, partial versus complete CrCL rupture, unilateral versus bilateral CrCL rupture, presence of meniscal tear. Treatment for meniscal damage, implant type, pre- and postoperative antibiotic drug therapy, duration of clinical follow-up and need for physiotherapy were also reported. Contralateral CrCL rupture was documented and time between the diagnosis of the two CrCL ruptures was measured. Any complications following surgery were recorded. The minimum follow-up period was 6 months.

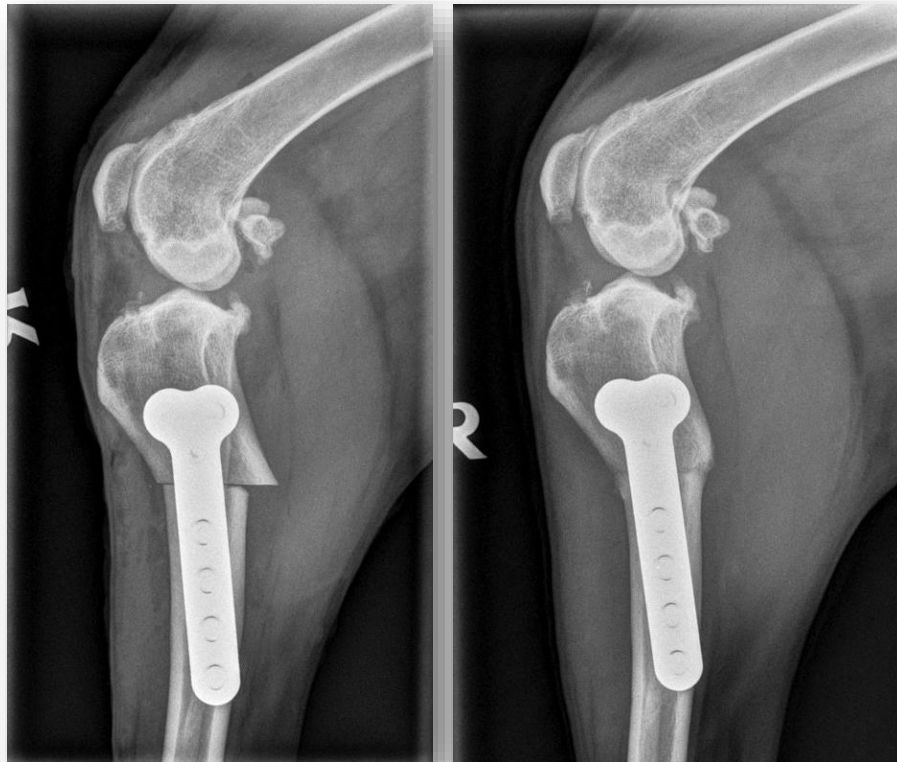
3. Radiographic assessment

All dogs had the affected stifle assessed radiographically and the presence of signs of joint effusion and osteophytosis were reported. Standard mediolateral and caudocranial radiographic projections were obtained. Mediolateral radiographs centred on the stifle but including the tarsus were taken for measurement of the preoperative TPA. For that purpose, major importance was given to obtain a radiograph in which the femoral condyles overlapped each other. Sandbags or foam wedges were used when necessary. Projections were repeated if there was not complete superimposition of the femoral condyles on the mediolateral projection.

Postoperative caudocranial and mediolateral radiographic projections were also assessed for completeness of osteotomy reduction and surgical implant positioning (plate(s) and screws).

Osteotomy healing and progression of OA were assessed subjectively by evaluation of the three-month follow-up radiographs with caudocranial and mediolateral projections of the stifle joint.

Figure 10: Lateral view radiographs of the right stifle of one dog that underwent CWO at KVG: immediately after surgery (Left) and 12 weeks postoperatively (Right), with evidence of bone healing.

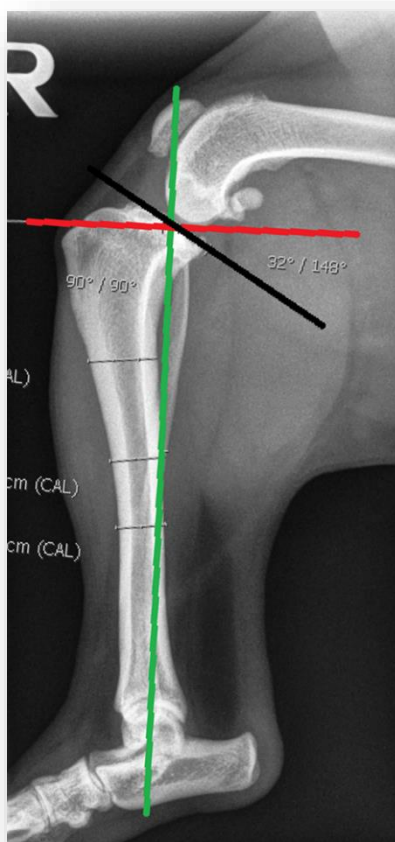


4. Procedures

4.1. Measurement of the TPA

All dogs that underwent CWO had preoperative TPA measurements. The preoperative TPA was determined from a lateral radiographic view of the tibia which included both stifle and tarsus joints, with the X-ray beam centred on the stifle joint. Functional tibial axis line was drawn, passing through a point at the centre of the talus and a point at the centre of the intercondylar eminences; medial tibial plateau line was drawn, connecting the cranial aspect of the medial tibial plateau to the caudal aspect of the medial tibial plateau line; a reference line was drawn, perpendicular to the functional tibial axis line; and finally the angle between the medial tibial plateau line and the reference line was measured corresponding to the TPA.

Figure 11: Tibial Plateau Measurement on a lateral view radiograph, including the stifle and hock joints. The functional tibial axis line (green), the medial tibial plateau line (black) and the reference line (red) allow the measurement of the TPA, corresponding to the angle between the medial tibial plateau line and the reference line.



4.2. Preoperative management

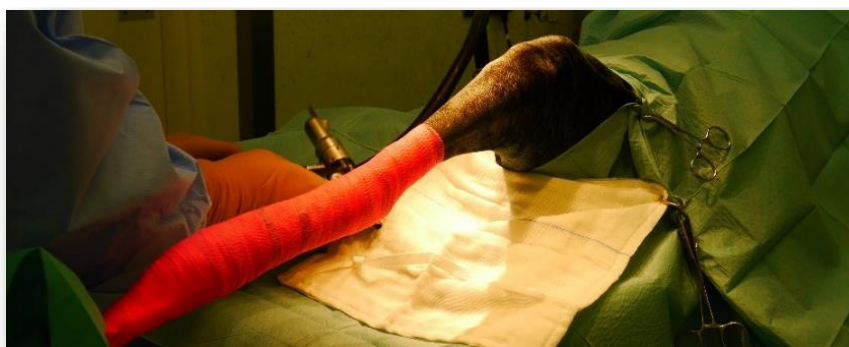Some dogs had radiographic assessment done on the same day immediately before surgery. Others were radiographically assessed on a previous date. Dogs to be only radiographically examined were pre-medicated with acepromazine (ACP, Novartis) (0.025 mg/kg) and buprenorphine (Vetergesic, Ceva) (0.02 mg/kg) by IM injection. Dogs to be submitted to surgery were pre-medicated with acepromazine (ACP, Novartis) (0.025 mg/kg) and methadone hydrochloride (Comfortan, Dechra) (0.5 mg/kg) by IM injection. Meloxicam (Metacam, Boehringer Ingelheim) (0.2 mg/kg) was administered by SC injection at premedication if patient was not already receiving NSAIDs orally. Induction was performed with propofol (PropoFlo, Abbott) (1-4 mg/kg) IV and maintained with Isoflurane. Ketamine (Ketaset, Fort Dodge) (0.5 mg/kg) was administered IV 5 minutes before surgery. Cefuroxime (Zinacef, GlaxoSmithKline) (20 mg/kg) was administered 20 minutes before surgery and repeated every 90 minutes during surgery. IV fluid therapy was initiated before surgery and consisted of a

constant rate infusion (CRI) of ketamine at the rate of 10 $\mu\text{g}/\text{kg}/\text{min}$ and a Hartmann's solution at maintenance rate, which was adjusted throughout surgery according to patient's response.

4.3. Surgical Technique

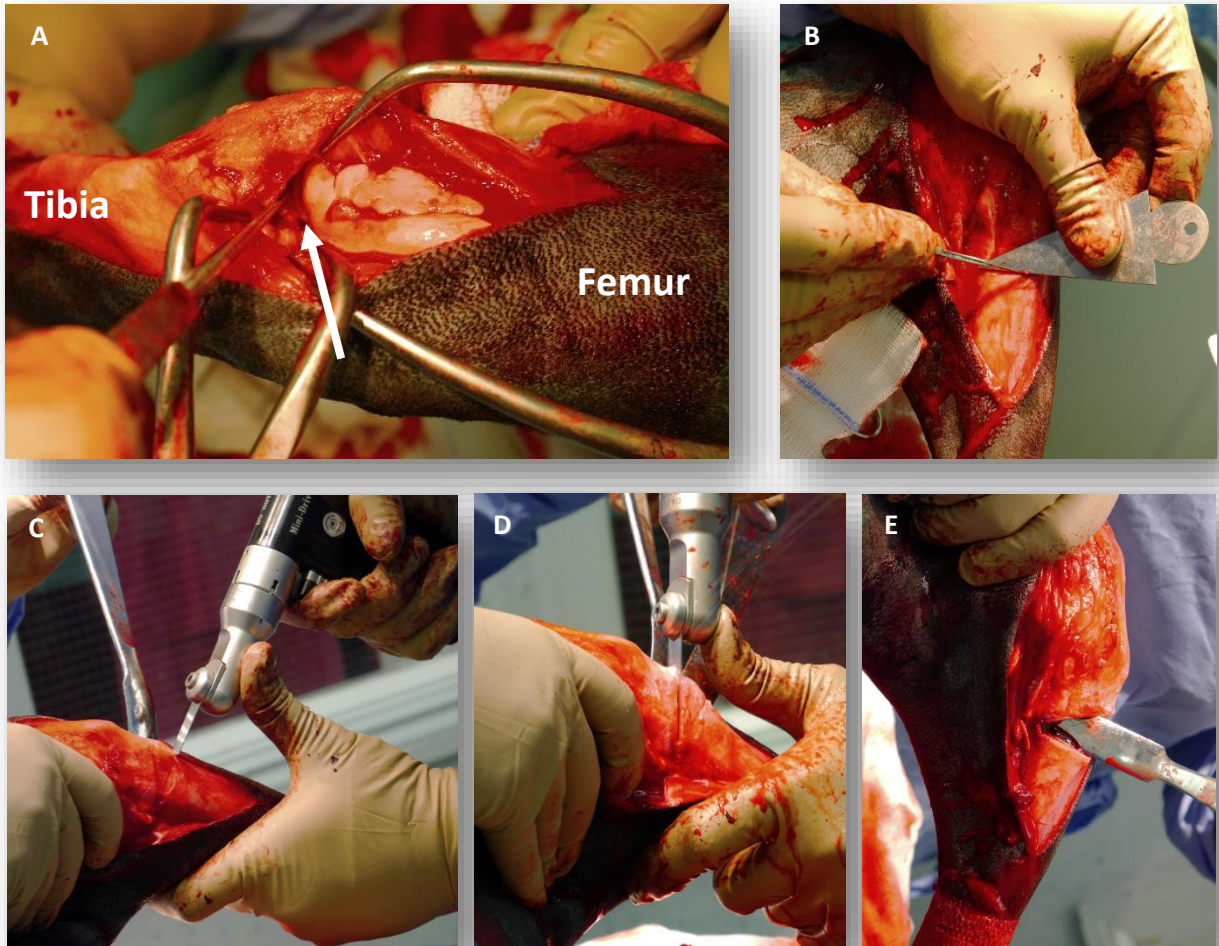
All dogs that underwent CWO were placed in dorsal recumbency. Disposable gowns, gloves and drapes were used. The surgeon double gloved for every procedure. The antiseptic agent used was composed of Chlorhexidine gluconate 0.5% w/v in 70% v/v IMS with a blue stain (Vetasept® Chlorhexidine Skin Scrub Blue, Animalcare). Also, hands were disinfected, prior to dressing and gloving, with an alcohol-based gel (Sterillium® Gel, Hartmann).

Figure 12: Positioning, draping and preparation for the surgical procedure.



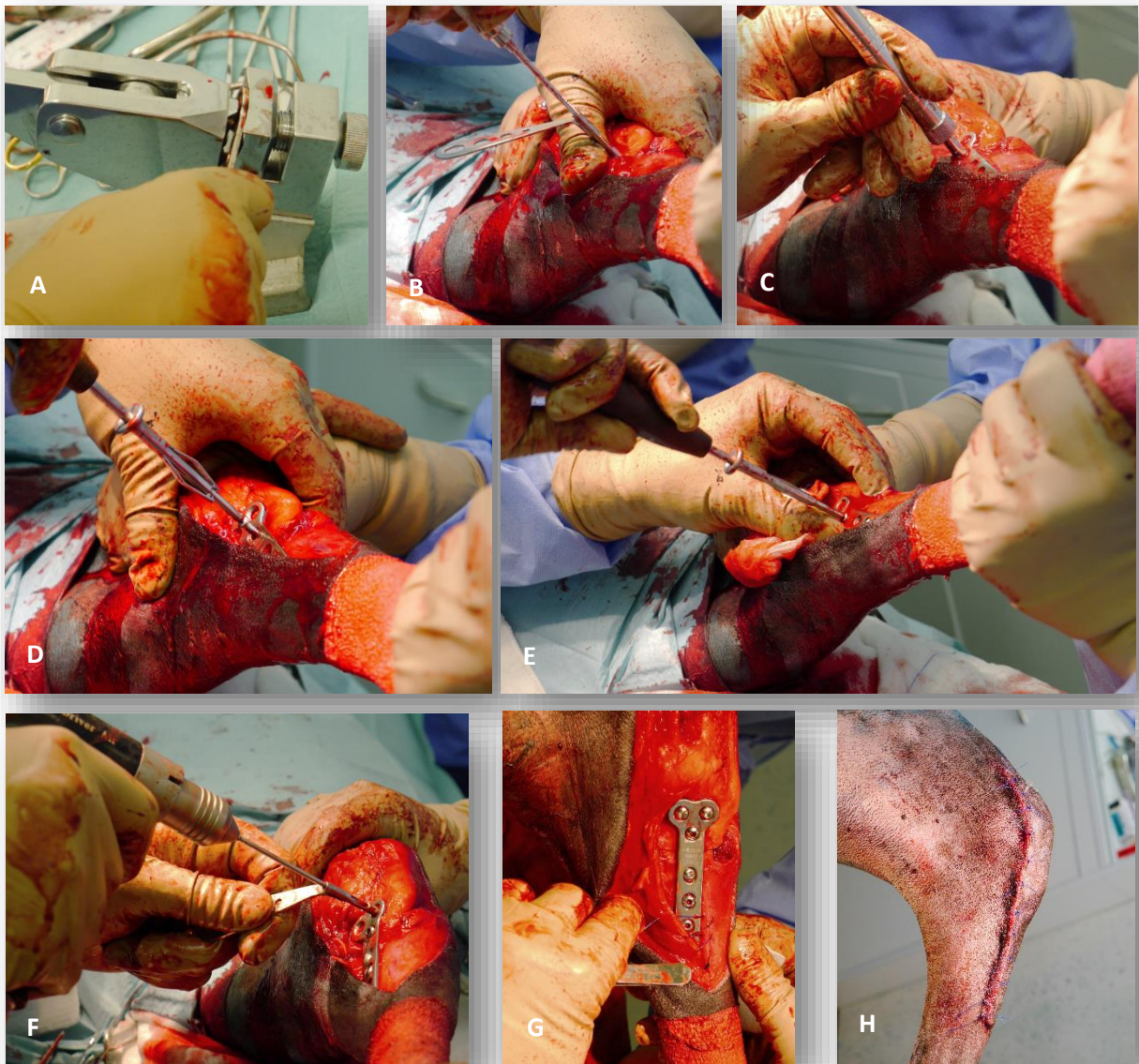
Exploration of the stifle joint before surgical stabilization was performed by craniomedial arthrotomy, using a No 15 blade, allowing evaluation of CrCL degree of damage (complete or partial rupture) and presence of degenerative joint disease. Remnants of the CrCL were removed and the menisci were checked for any injuries. Small stifle retractors were used to facilitate access to the menisci. Menisci were assessed for any injury with the aid of a meniscal probe. Whenever meniscal damage was present, debridement by partial or complete meniscectomy was performed using a No 11 blade. Initially, all intact menisci were left in situ; however, in later cases a medial meniscal release was performed by transection of the caudal meniscotibial ligament when the menisci appeared loose or fraying. Then the incision was extended to expose the medial proximal tibia. Using the measurements of the preoperative TPA the angle of the wedge to be removed was calculated aiming a final TPA of 5° (=preoperative TPA minus 5°).

Figure 13: First steps of CWO procedure. (A) Arthrotomy and examination of the structures in the stifle joint, in this case, a medial meniscal release was performed and the medial meniscus (white arrow) is shown. (B) The angle for the wedge osteotomy is delineated with the aid of a wedge osteotomy template. (C) A Hohmann retractor is used to help performing the osteotomy. (D) The two osteotomies are performed while the site is being irrigated with saline solution. (E) After osteotomy.



Then a wedge template, with the appropriate angle was used to accurately mark the correct wedge shaped osteotomy on the proximal third of the tibia. By making the wedge an isosceles triangle on reduction the cranial and caudal borders of the tibia remained congruent and an attempt was made to preserve a small “hinge” of intact caudomedial cortex. Osteotomies were performed using an oscillating saw and the surgical area was irrigated with sterile saline solution during this step. A tibial wedge was then removed. Care was taken to ensure both cut surfaces were clean and smooth with no spurs to facilitate the reduction and compression of the osteotomised site. The osteotomy was then reduced with the cranial and medial cortices in alignment and the tibia was held straight by an assistant.

Figure 14: Some steps of CWO procedure. (A) Contouring the plate. (B) Tapping a hole. (C) Measuring the size of the screw needed for a hole. (D&E) Placing a screw in compression (first screw). (F) Drilling a hole. (G) Beginning to suture after placement of the implants. (H) Surgical site after closure.



Adjustments were made in order to achieve the perfect alignment. The plate was contoured as necessary and then was fixed in compression mode on the medial aspect of the proximal tibia. A minimum of 3 screws were engaged in each of the tibial fragments, taking care not to place the screws intra-articularly. One or two 4.0 mm cancellous screws were used in the proximal fragment and the remaining were cortical screws. Dogs weighing more than 35 kg had two plates placed. Lavage of the surgical field was performed with saline solution prior to closure. Routine layered closure was executed. A sterile adhesive dressing (Primapore, smith&nephew) was applied for 24 hours.

4.4. Postoperative management

All dogs had another dose of methadone hydrochloride (Comfortan, Dechra) (0.5 mg/kg) 4 hours after the previous one given at pre-medication. In further 4 hours, opioid pain relief was continued with buprenorphine (Vetergesic, Ceva) (0.02 mg/kg) IV in intervals of 6 hours and a CRI ketamin (Ketaset, Fort Dodge) at a rate of 2 µg/kg/min through the 12 to 18 hours following surgery.

The following day oral medication was introduced and consisted of paracetamol (Pardale V, Dechra) (10 mg/kg) three times daily for 7 days, NSAIDs at the recommended dose for 4 to 8 weeks, usually decreasing to half-dose at 4 weeks, cefalexin (Rilexine, Virbac) (20 mg/kg) twice daily for 7 days and tramadol (Tramadol, Actavis) (2-5 mg/kg) twice or three times daily for 7 days too. Dogs were typically discharged from the hospital 48 hours after surgery. Upon discharge, the patient's home-care was thoroughly discussed with the owner to allow understanding of exercise restriction, analgesia and wound care. Strict rest was recommended during the first week after surgery, lead exercise for five to ten minutes twice daily the following two weeks and then increase lead exercise to ten to fifteen minutes twice daily. Physiotherapy, particularly water treadmill, was suggested in all cases after this period of time and progressive increase of exercise was recommended.

All dogs were returned at four to six days following surgery for physical examination and evaluation of recovery. Again, at ten to fourteen days after surgery, for skin suture removal. Patients with expected improvement were only re-evaluated one month after. However, owners were encouraged to bring their dogs for clinical examination if there was any concern. Three months following surgery, radiographic examination was performed to evaluate healing status of the osteotomy site and progression of OA, which was subjectively characterised by the veterinary surgeon based on comparison of radiographs with those taken immediately after surgery, classifying it into severe, moderate, little and no progression of OA. According to healing status of the osteotomy site adaptations in exercise activity were suggested by the surgeon and discussed whether or not further radiographic assessment would be required in the future. Whenever radiographic healing was noted, a gradual increase of exercise was recommended during the subsequent 4 weeks. The goal was to return to normal activity by that period of time.

5. Complications

Type and outcome of complications were recorded. All complications that occurred intra- and postoperatively were considered. Complications were defined as any unexpected and undesired development arisen during or after surgery, which were confirmed by direct visualization, physical or radiographic examination. Complications were also separated in major and minor: the first were defined as those complications requiring further surgical treatment and the second as those not requiring additional surgical intervention.

III. RESULTS

1. Signalment

CWO for CrCL repair was performed in 108 dogs (145 stifles), 51 females (47.2%), from which 32 were spayed (29.6%) and 19 were intact (17.6%), and 57 males (52.8%), from which 38 were castrated (35.2%) and 19 were intact (17.6%). The mean age at time of surgery for first time CrCL repair was 5.3 years (range 0-12 years) and the mean body weight was 28.1 kg (range 7.3-69.4 kg). There were 19 Labrador Retrievers and their crosses (17.6%), 12 Boxers (11.1%), 7 Rottweilers and their crosses (6.5%), 6 Mastiffs and their crosses (5.6%), 5 Jack Russel Terriers (4.6%), 4 Cocker Spaniels and their crosses (3.7%), 3 West Highland Terriers (2.8%), 3 Staffordshire Bull Terriers (2.8%), 3 English Bulldogs (2.8%), 3 Collies (2.8%), 3 Beagles (2.8%), 3 German Shepherds and their crosses (2.8%), 2 English Springer Spaniels (1.9%), 2 Japanese Akitas (1.9%), 2 Golden Retrievers (1.9%), 2 Bichon Frise and their crosses (1.9%) and 1 each (0.9%) of the following breeds: Yorkshire Terrier, Tibetan Terrier, Spanish Water Dog, Siberian Husky, Newfoundland, Czesky Terrier, Bull Terrier, Border Terrier, American Bulldog. The remaining 20 dogs (18.5%) were undetermined cross breeds.

2. Radiographic and Surgical findings

CWO was performed in 145 stifle joints (68 left [46.9%] and 77 right [53.1%]). Thirty-seven dogs (34.3%) had bilateral CWO, with the second procedure performed at varying intervals after the first with a mean of 13.3 months (range 0 to 47 months). Only one patient had bilateral CWO performed under the same anaesthetic procedure. Six patients had bilateral CrCL disease diagnosed at first radiographic examination. All 145 stifle joints were examined via arthrotomy. The degree of rupture of the CrCL was reported in 122 cases of the CWO procedures where complete rupture occurred in 88 cases (72.1%) and partial rupture in 34 (27.9%). Only 132 clinical records mentioned presence or absence of meniscal injuries. Meniscal injuries, particularly bucket handle tears and transverse tears, were noted in 63 (47.7%) stifles, being debrided by partial or complete meniscectomy. Seven (5.3%) medial menisci were frayed and in one a lesion was suspected so medial meniscal release was performed in such cases. No evidence of meniscal tear was reported in 62 (47%) cases but 16 (12.1%) appeared loose, being performed a medial meniscal release in these cases. A medial meniscal release was also performed in 12 of the 62 cases where there was no evidence of meniscal tear. Thirty-four (25.8%) intact menisci were left in place. Total meniscectomy was performed in 7 (5.3%) cases. The medial meniscus was debrided in 56 (42.4%) cases, 12 of which had a medial meniscal

release too. In 35 (26.5%) cases only a medial meniscal release was performed, of which 12 had no evidence of meniscal tear and the remaining 23 were either loose or fraying.

Although the preoperative TPAs were measured in all cases they were only reported in 92 of the clinical records with a mean of 30.3° (range 21° to 50°). Postoperative TPAs were not measured.

3. Radiographic re-evaluation and follow-up

In-hospital evaluation and radiographic assessment of healing occurred in 110 cases from 6 to 19 weeks post-operatively. Mean duration of clinical follow up was approximately 2 years (range 6 to 85 months). All dogs were examined for stifle joint stability on follow up appointments and owners were questioned about lameness and function improvement. On radiographic examination, healing progress was evaluated and progression of OA documented when identified. From the 110 cases that had radiographic re-evaluation, 12 (11%) still presented a mild line of radiolucency in the osteotomy site and, therefore, had to return for further radiographic evaluation within a few weeks, all displaying healed osteotomy site at second radiographic follow-up. Also, one case did not heal within the expected time, representing a delayed union. Little to no progression of OA was reported in all evaluated cases apart from one that exhibited moderate progression of OA.

4. Complications

Post-operative complications were reported for 27 (18.6%) of the 145 stifle joints. Of these, 5 (3.4%) were classified as major complications (Table 1) and 22 (15.2%) as minor complications (Table 2).

4.1. Major complications

Major complications included three implant failures (2.1%) and one each (0.7%) of subsequent meniscal tear and non-union due to infection.

One dog was presented 7 months postoperatively limping and during orthopaedic examination an audible click could be heard during flexion of the stifle joint and some effusion could be palpated. Initially, radiographic examination was elected in order to rule out sinister diagnosis such as bone tumours. Subsequent meniscal tear was suspected and, therefore, lateral approach for arthrotomy was performed and a thorough examination of the stifle joint was achieved, confirming the presence of a medial meniscal tear. Medial meniscectomy was performed and a biopsy of synovium was collected for histopathology and bacterial culture to rule out other possible concurrent conditions such as neoplasia or infection. The bacterial culture result was

negative and the histopathologic exam showed minimal lymphocytic plasmacytic synovitis and low grade inflammatory changes with no signs of infectious process, which was consistent with response to meniscal injury. The patient's limb function was much improved approximately 2 weeks after the intervention.

There were 3 implant failures, 2 consisted of broken screws and 1 of loosen screws. First case was presented with persistent lameness that did not improve with previous NSAID therapy. Radiographic examination was recommended and fracture of the proximal cancellous screw was identified. Implants were surgically removed and replaced, although the shaft of the screw was not retrievable and was left in place. The patient recovered well and returned to normal function. Second case, 2 broken implants were diagnosed on radiographic examination (2 proximal 4.0 mm cancellous screws from the 4hole 3.5 mm plate). However, the bone had already healed and replacement of the implants was not needed.

Third case, implant failure occurred one month after surgery, where clinical and radiographic examination identified the instability of the stifle due to looseness of proximal screws. These implants were removed surgically and replaced.

A single case of non-union due to infection was reported. The patient had persistent lameness that had not responded to previous NSAID therapy and on radiographic examination non-union was suspected. Implants were surgically removed and replaced. Screws were sent for microbial culture and antibiotic sensitivity test, which revealed presence of coagulase negative *Staphylococcus*. Antibiotherapy had been started with metronidazole and amoxicillin associated to clavulanic acid and was then changed to enrofloxacin (Baytril, Bayer) and amoxicillin associated to clavulanic acid (Noroclav, Norbrook) and continued for approximately 20 weeks. After bone healing, assessed radiographically, all implants were removed to prevent future infection. The patient returned to normal function.

Three patients were presented with lameness, respectively, 4months, 6months and 8months after surgery. Subsequent meniscal disease was suspected in all of them. However, only one was submitted to further diagnostic tests consisting of arthrocentesis for collection of synovial fluid for bacterial culture and cytology. The bacterial culture was negative and the cytology results were consistent with degenerative joint disease which could also be related to meniscal injury. Arthrotomy was recommended by the surgeon but was declined by the owner, and therefore there is no further record of the patient as the client did not attend more appointments. Conservative management was opted in the other two cases, with the patients having shown pronounced improvement over the following two to three weeks.

Table 1: Major complications (defined as subsequent surgical intervention) following Tibial Plateau Levelling by Closing Wedge Osteotomy in 145 stifle joints in 108 dogs

Complication	Number of cases	Additional details	Treatment	Outcome
Subsequent meniscal tear	1	7 months postoperative, audible click during flexion, some palpable effusion	Stifle joint re-exploration, meniscectomy	Returned to normal function within 8 weeks
Implant failure/Broken screws	2	One 4.0 mm cancellous screw, and two 4.0 mm cancellous screws fractured	Implant removal and replacement. Shafts of cancellous screws were left <i>in situ</i>	Healed within 6 weeks, resolution of lameness
Implant failure/Loosening screws	1	One month postoperative, stifle instability. X-rays showed 3 proximal screws loosening	Implant removal and replacement	Healed within 6 weeks, resolution of lameness
Infection/Non-union	1	Lameness 4 months postoperative, non-union suspected on X-rays, screws sent for culture and sensitivity, coagulase negative staphylococcus infection	Implant removal and replacement, antibiotherapy for 5 months. Implant removal after bone healed	Infection resolved, resolution of lameness

4.2. Minor complications

Minor complications included wound infection, oedema of the hock, broken drill bits, iatrogenic fibular fracture, bruising due to surgical trauma, broken screws and loosen screws (Table 2).

One (0.7%) iatrogenic diaphyseal fibular fracture was reported. No clinical signs associated with this condition were described and at radiographic re-evaluation, 14 weeks after surgery, there was evidence of bone healing.

Thirteen (9%) surgical wound infections were reported in the short-term period following surgery. From these, only two had diagnostic confirmation with bacterial culture. One revealed growth of *Staphylococcus pseudointermedius*, showing sensitivity to amoxicillin associated to clavulanic acid, having resolved after 2 weeks of treatment with the appropriate antibiotic. The second showed growth of *Pseudomonas aeruginosa* and was treated with metronidazole and enrofloxacin for 2 weeks, after which period of time there were no signs of infection. The remaining cases of wound infection were diagnosed based on the clinical signs (redness, swelling, wound discharge) and empiric antibiotherapy was instituted, with the most common choices of antibiotic being amoxicillin associated to clavulanic acid and cephalexin, with duration of therapy varying from one to two weeks.

Oedema of the hock was noted in 3 patients (2.1% of the cases) and resolved in 1 to 2 weeks with massage and cold compression applied to the affected area together with continuation of NSAID therapy.

There was 1 case of extended bruising around the surgical site and abundant swelling resultant from surgical trauma, which resolved after 2 weeks while the patient was still on NSAID therapy and antibiotherapy.

There were 2 cases (1.4%) of broken drill bits, which had to be left inside the bone as were not retrievable. Both were radiographically evaluated 12 weeks following surgery for possible migration of the broken drill bit. There were no associated clinical signs in both patients and post operative outcome was predictable and normal.

Two implant failures not requiring second surgical intervention were reported and occurred in only one patient that had bilateral CWO surgery with an interval of 8 months between the two procedures. Regarding the first operated limb, the patient had had the expected improvement and the osteotomy site had been evaluated at 13 weeks post-CWO procedure, having healed well. The patient was presented 2 years after surgery with lameness and stifle joint effusion. Radiographic examination was accomplished, allowing detection of 2 broken screws in the proximal fragment. Therapy with NSAIDs was instituted, resolving clinical signs within 4 weeks. A similar situation was observed in the second operated limb 16 months after CWO procedure, but on radiographic examination 2 screws appeared loosening in the proximal fragment. The same protocol was applied and the patient showed no clinical signs after 3 weeks of NSAID therapy.

Table 2: Minor complications (defined as no further surgical intervention) following Tibial Plateau Levelling by Closing Wedge Osteotomy in 145 stifle joints in 108 dogs

Complication	Number of cases	Additional details	Treatment	Outcome
Iatrogenic fibula fracture	1	Fibula fracture occurred intraoperatively. No clinical signs	Monitoring bone healing via radiographic examination	Healed well
Surgical wound infection	13	Delayed wound healing, oedema, redness and discharge	Buster Collar, Antibiotics	All resolved within one to two weeks
Oedema, hematoma, bruising	4	Three patients had oedema of the hock and one extensive bruising around surgical incision	Massage and cold compression, NSAIDs	Resolved within one to two weeks
Broken drill bits	2	During surgery the drill bit broke and was not retrievable	Monitoring for migration via radiographic exam	No clinical signs associated
Broken screw	1	Lame two years postoperative, joint effusion. On X-rays broken screws in the proximal fragment	NSAID therapy	Resolved within 4 weeks
Loosening screw	1	Lame sixteen months postoperative, on X-rays suspected screw loosening on proximal fragment	NSAID therapy	Resolved within 2 weeks

IV. DISCUSSION

All patients that underwent CWO surgery for CrCL disease performed by one surgeon between August 2007 and November 2015 with more or at least 6 month follow-up were included in the study. A minimum of 6 months postoperative for long-term follow-up has been used by other authors (Oxley et al., 2013). However, some of the complications reported occurred later than 6 months postoperatively. Therefore, the most recent cases analysed may still develop complications in the future, which are beyond the scope of this work.

Diagnosis of CrCL rupture, in this study, was based on clinical findings evaluated in the conscious patient followed by examination under anaesthesia together with radiographic findings. Arthroscopy was not available, therefore, confirmation of CrCL rupture along with the degree of damage to the ligament was only achieved by direct visualisation during surgery via arthrotomy. Cranial drawer test was performed in all cases with the stifle joint in flexion and in extension, to avoid false negative results that might result from partial tears when the cranial drawer test is only performed in extension. Radiographic examination was essential for identification of joint effusion and osteophytosis, allowing a more accurate diagnosis as radiographic assessment has shown excellent sensitivity and specificity in detecting canine CrCL failure (Carobbi & Ness, 2009).

Since CWO aims reduction of the preoperative TPA, determination of the TPA is one of the most imperious aspects of preoperative planning (Slocum & Devine, 1983) considering the fact that obtaining a different postoperative TPA from the desired may affect the outcome of surgery either by increasing caudal tibial thrust and, consequently, increasing CaCL strain (by removing a larger wedge) or by failing in achieving stifle joint stability (by removing a smaller wedge) (Warzee et al., 2001). For that reason, accurate initial preoperative measurement of TPA is necessary to achieve the desired postoperative TPA (Fettig et al., 2003). It has been shown that limb positioning is essential to accurately calculate the radiographic TPA and that it is not significantly different from the anatomic TPA. Incorrect limb positioning may lead to over- or underestimation of the TPA (Reif et al., 2004). In our study, true lateral positioning of the affected limb was confirmed by superimposition of the femoral and tibial condyles, thereafter, allowing an accurate TPA determination (Reif et al., 2004) and, consequently, an accurate calculation of the wedge to be removed. It has been previously suggested that removing a wedge equivalent to the preoperative TPA minus 5° would result in under-correction of the TPA (Bailey et al., 2007). However, this fact was never taken into consideration for the cases in this study. Moreover, the postoperative TPA was not measured routinely, which did not allow the

confirmation of the desired TPA. Nevertheless, according to clinical records, 98% of the dogs either returned to normal function or improved significantly, which rises doubt about the clinical relevance of the accuracy of obtaining the desired postoperative TPA.

Postoperative radiographic assessment allowed subjective evaluation of bone healing, implant integrity or migration, and progression of OA. Regarding the presence of OA in the joint, previous studies show no correlation with clinical function; therefore, radiography should be used cautiously as a predictor of clinical outcome (Gordon et al., 2003; Dieppe, Cushnaghan & Shepstone, 1997).

Prophylactic antibiotherapy is one important aspect in orthopaedic surgery, since studies have shown that even with ultra-clean theatres, prophylactic antibiotics reduce the risk of infection, where an implant is being used (Yeap et al., 2006). Selection of the antibiotic should take in account the microorganisms of concern in clean orthopaedic surgery, which are mainly the bacteria found on the skin. For such procedures, cefuroxime, a second-generation cephalosporin, was the antibiotic of choice in our practice because it provides adequate coverage against most staphylococci, gram-positive bacteria and some gram-negative bacilli, and also due to the fact that it rapidly achieves optimal tissue concentrations in subcutaneous tissue, muscle and bone.

The Sterillium Gel, used for hand disinfection prior to dressing and gloving, has been proved to have a unique spectrum of antimicrobial activity and had an excellent acceptance by healthcare workers, therefore, it is thought to improve compliance for hand hygiene and reduce incidence of nosocomial infections (Kampf, Rudolf, Labadie & Barrett, 2002). Also, the use of disposable gowns and draping materials may have contributed to reduce risk of infection, as it has been associated with less bacterial transmission and lower rates of contamination than reusable materials (Ward et al., 2014; Showalter et al., 2014). There is no direct evidence that double-gloving reduces surgical site infections in patients, however, it significantly reduces perforations to the innermost gloves, contributing positively to assure sterility (Tanner & Parkinson, 2004). The skin scrub used (Vetasept Chlorhexidine Skin Scrub Blue) is a safe and effective disinfectant with broad spectrum antibacterial and antiviral activity, highly active against gram-positive organisms, including MRSA (Miller, Griffin & Campbell, 2012).

Extrapolating from studies in Human Medicine, patients suffer more from severe immediate postoperative pain following orthopaedic surgery than laparotomy (Ekstein & Weinbroum, 2011). Therefore, opioid therapy is recommended as it has proved its efficacy in pain management in such cases (Hunt, Attenburrow, Slingsby and Murrell, 2013). Also, it has been

suggested that perioperative administration of low doses of ketamine to dogs may augment analgesia and comfort in the postoperative surgical period (Wagner, Walton, Hellyer, Gaynor & Mama, 2002). Therefore, all cases reviewed had opioid drug management in the perioperative period which was continued with oral tramadol at home for 7 days, after the patient being discharged from the hospital. However, tramadol is not licensed for use in small animal practice and there are currently only a small number of studies documenting analgesic efficacy of this drug in dogs (Martins et al., 2010; Mastrocinque & Fantoni, 2003). Therefore, although opioid drugs are widely used for postoperative analgesia in dogs, their administration is normally restricted to the period of hospitalisation, which limits the possibility of continuing a multimodal pain relief at home, possibly leading to inadequate analgesia. In the short-postoperative period pain assessment is very important in the decision making of discharging a patient. In our study, most dogs went home 48 hours after surgery. However, considering pain assessment records, some had to extend their hospitalisation period to guarantee adequate pain relief.

Common to all surgeries that require osteotomies or implant placement, during CWO procedure, temperature produced by certain instruments was taken into account. Excessive temperatures can result in osteonecrosis or in impairment of osteogenic potential (Eriksson, Albrektsson & Magnusson, 1984). Necrotic bone is reabsorbed by the osteoclasts, what ultimately may result in failure of implant fixation. During osteotomy and while drilling the mechanical work energy is converted into thermal energy causing a transient rise in temperature of adjacent tissues above the normal physiological levels. In an attempt to limit the effect of high temperatures on the tissues, intraoperative temperature abatement strategies can be used. Therefore, irrigation with sterile saline while performing osteotomies was employed to guarantee bone viability. Time required for drilling the holes was much shorter, not justifying the use of this strategy.

Non-self-tapping screws were used due to surgeon's preference. These are round-tipped screws that require pre-drilling of a pilot hole and then tapping (creation of a thread in the bone by using a separate thread-cutting tool – a tap). The disadvantages of self-tapping screws is that if a screw is being reinserted it could theoretically cut a new thread. Also, self-tapping screws have shown a significantly higher incidence of transcortical fractures in a canine TPLO model, possibly due to the shorter cutting flutes of the self-tapping screws as compared with those of a tap used with a non-self-tapping screw (Boekhout & Cross, 2012). On the other hand, extrapolating from a study with horses, self-tapping screws require less than half the total insertion time of non-self-tapping screws, which extends the surgical time and, consequently,

the anaesthetic time along with its associated risks. However, in our study, the average time for the surgical procedure was 80 minutes (when one single plate was required), which is comparable to previously reported median time for CWO (Kuan et al., 2009) although screw type used was not specified in that study.

In this retrospective study, CWO was performed in 108 dogs (145 stifles) and complications associated with the procedure were evaluated. Depending on their clinical relevance, complications are commonly reported as either major or minor (Cook et al., 2010). Although this is a subjective judgement, in this study, the need to perform a second surgery was the threshold between major and minor. Other studies have used similar classification systems (Kuan et al, 2009; Lafaver et al., 2007). However, this may have produced some anomalies and some complications would more likely be classified in the opposite area considering their severity or lack thereof, notwithstanding requiring further surgical intervention or not. For example, one of the cases of broken screws that required surgical removal of the implants could possibly be considered a minor issue despite use of surgery for resolution, since stifle stability was not compromised.

In this study, 9% surgical wound infection was registered. Such rate is comparable to previously published infection rates following TPLO surgery, which vary from 3% to 10.3% (Stauffer et al., 2006; Priddy et al., 2003). Conversely, it is higher than those rates previously reported for clean-wounds which vary from 5.1% (Vasseur et al., 1988) to 5.8% (Eugster et al., 2004). These results may be associated to the prolonged anaesthetic time required for CWO surgery with the aggravating circumstance of performing pre- and postoperative radiographs, which has been considered a risk factor for postoperative wound infection in animals with clean surgical wounds (Beal, Brown & Shofer, 2000; Eugster et al., 2004). Also, prolonged operating time is associated to increased bacterial contamination and the excessive retraction and dehydration of the tissues has an evidently harmful effect, compromising the tissue capability to resist infection. Furthermore, given the retrospective nature of this study, confounding variables, such as possible disruptions in aseptic technique, were not specifically recorded, which may have potentially affected the results. Additionally, there could be an overestimation of surgical wound infection. An inflammatory response during early wound healing may differ from patient to patient and be more exuberant in some cases, not necessarily implicating presence of infectious agents but leading to use of prophylactic antibiotics when in doubt. In fact, only 2 of the 13 cases classified as wound infection were confirmed with positive bacterial culture.

Meniscal injury occurred here in 63 cases. According to the literature, incidence of meniscal injury secondary to CrCL disease is approximately 40% to 70% (Flo & DeYoung, 1978;

Bennett & May 1991; Flo, 1993; Ralphs & Whitney 2002; Fitzpatrick & Solano 2010). Consequently, surgical exposure of the stifle joint during arthrotomy is of major importance in order to appropriately evaluate the menisci and provide treatment as required. Subsequent meniscal disease is one of the most common complications seen after CrCL repair, regardless of the repair technique, with an overall incidence of approximately 3% to 6% (Gordon-Evans et al., 2013; Nelson et al., 2013; Oxley et al., 2013; Hirsheson et al., 2012). The rate of incidence of subsequent meniscal tear in the present study was 0.69%, with only one case being confirmed and reported between all 145 stifle joints. The patient in question did not have medial meniscal release nor had any treatment applied to the meniscus. The low rate is probably related to the methodical joint exploration via arthrotomy, with accurate identification of meniscal tears and its correct management by performing partial, hemi- or total meniscectomy according to the degree of meniscal damage. Also, medial meniscal release was performed in the majority of cases that had no evident meniscal tear but looked either loose or appeared to be fraying at the caudal horn and in some cases where there was no evidence of meniscal tear. Subsequent meniscal tear was suspected in three other cases that, at the time of CWO, did not have medial meniscal release nor was any treatment performed as no meniscal injury was detected. However, confirmation via arthrotomy was not attained. In the clinical records of two of these patients there was no mention of audible click and clinical signs resolved after 2 weeks of NSAIDs therapy which would not be predictable in the presence of a meniscal tear as they normally cause persistent lameness if left untreated (Thieman, Tomlinson, Foz, Cook & Cook, 2006; Case et al. 2008). In contrast, pain on manipulation of the stifle joint and an audible click during flexion on clinical examination were reported for the other patient. Though, the owner refused further investigation, and definitive diagnosis was not achieved. Nevertheless, a painful stifle joint and an audible click during flexion increases the likelihood of medial meniscal disease 4.3 and 11.3 times, respectively (Dillon et al., 2004). In that case, considering the likelihood of the case, the rate of subsequent meniscal injury would have been 1.4%, increasing overall complication rate to 19.3%. However, at least two of these cases recovered after 2 weeks of NSAID therapy which would not be predictable in the presence of a meniscal tear as they normally cause persistent lameness if left untreated (Thieman et al. 2006; Case et al., 2008). It is noteworthy mentioning that this complication resulted from one of the 50 first cases performed by the surgeon. The lack of subsequent meniscal tears in the later cases may correlate to the learning curve as surgical techniques of exposure and detection of meniscal lesions allied to the precision of their management, while reducing risk of iatrogenic injury to the cartilage, improved along with the surgeon's experience over time.

There were no cases of confirmed or suspected subsequent meniscal disease occurring after medial meniscal release performed at the time of CWO. It has been suggested that performing a meniscal release may be advantageous when meniscal pathology cannot be comprehensively assessed and should be performed when complete and thorough exploration of the joint and menisci cannot be performed (Thieman et al., 2006). Subsequent meniscal tears are 3.8 times more likely to occur when meniscal evaluation is performed by arthrotomy and no meniscal release is performed when compared to either meniscal evaluation via arthrotomy with a release performed or meniscal evaluation via arthroscopy with no release (Thieman et al., 2006). However, in other studies, meniscal release has been associated with articular loss, further meniscal pathology, degenerative joint disease and lameness; therefore, when making clinical decisions regarding meniscal release, these factors should be considered (Luther et al., 2009; Johnson et al., 2008).

There were 3 cases of implant loosening (2.1%). One of them was classified as a minor complication as the patient was only presented with lameness sixteen months after CWO surgery, osseous union had already occurred and no stifle instability was detected at clinical examination, with clinical signs resolving with NSAID therapy. However, the other patient required implant removal and replacement as the osteotomy site had not healed completely and stability was compromised. Diagnosis was based on radiographic findings, which included radiolucency around the implant in the first two cases and delayed healing in the later. Screw loosening rates previously reported following TPLO surgery rounded 1% of the cases (Stauffer et al., 2006; Pacchiana et al., 2003; Priddy et al., 2003). In contrast, screw loosening occurred in 6.7% of the 300 cases analysed by Kuan, Smith and Black (2009) following CWO. Screw loosening is an infrequent complication but the most common form of implant failure and may be related to failure of obtaining bicortical screw placement, excessive postoperative exercise, infection or excessive micromotion at the osteotomy site (Griffon & Hamaide, 2016). The cases revised most likely resulted from excessive postoperative exercise as no other cause was mentioned on the clinical records of the patients apart from that. Proper technique for plate contouring and bicortical screw fixation associated with postoperative exercise restriction are crucial measures that were taken into consideration by the surgeon, hence, the few cases revealing this complication.

There were 3 cases of broken screws. One patient was presented with lameness and stifle joint effusion on the operated limb two years following surgery. This was classified as a minor complication because no further surgery was required as radiographic examination revealed complete bone healing and no stifle joint instability was noted at physical examination.

Therefore, NSAID treatment was instituted and clinical signs resolved within 4 weeks. The other two patients required a second surgical intervention. One only required implant removal as the osteotomy site had healed completely, but the other required replacement of the implants as union was not still established. The rate of 2% obtained is comparable to those of 0.1% to 9.5% (Fitzpatrick & Solano, 2010; Conkling, Fagin & Daye, 2010; Corr & Brown, 2007; Pacchianna et al., 2003; Priddy et al., 2003) previously reported following TPLO procedure.

Implant-associated infections are major complications because they are especially difficult to treat due to formation of biofilm, usually requiring implant removal for resolution (Patel, 2005; Darouiche, 2004; Fine & Tobias, 2007; Donlan, 2001). There was only one reported case of non-union due to infection in the current study. Surgery was imperial for removal and replacement of implants and screws were sent for bacterial culture and antibiogram. Antibiotherapy was initiated immediately with a combination of metronidazole (Metronidazole, Actavis) and amoxicillin/clavulanic acid (Clavaseptin, Vétoquinol). According to studies based on culture and susceptibility, amoxicillin/clavulanic acid is considered the best first choice in empirical treatment of suspected implant-associated infections with a 67% rate of susceptible cultured organisms (Gallagher & Mertens, 2012). However, for the patient in question, results from the bacterial culture and antibiogram showed growth of coagulase negative *Staphylococcus* sensitive to enrofloxacin, at which point therapy was adapted and a combination of enrofloxacin (Baytril, Bayer) and amoxicillin/clavulanic acid (Clavaseptin, Vétoquinol) was implemented. Follow-up radiographs at 4 weeks showed initial callus formation and at 12 weeks complete bone healing. Although there was no clinical signs of infection at that stage, implants were surgically removed as a prophylactic measure, which is understandable considering the fact that the implants had been placed while infection was still in place, therefore carrying a potential risk for biofilm formation. Biofilms are a mixture of microorganisms and extracellular matrix which develop through bacterial adherence via tissue ligands present on the implant, creating a protective environment by depletion of metabolic substrates and waste products which limits the effectiveness of host immune response and increases resistance to antimicrobial agents (Patel, 2005; Darouiche, 2004; Fine & Tobias, 2007; Donlan, 2001). The rate of implant-associated infection in our study was 0.7% which is lower than the reported 7.3% of cases that developed osteomyelitis following TPLO procedure reported by Priddy et al., (2003), representing the single most common complication in that study, and the 2.7% reported by Fitzpatrick et al. (2010). Moreover, it is lower than the approximately 5% rate of orthopaedic implant-associated infection reported in humans (Trampuz & Zimmerli, 2006). CWO procedure is a technique where risk factors for

infection/osteomyelitis are present, including soft tissue trauma, relatively long duration of surgery and placement of implants. However, the low rate obtained is related to the properly planned surgical procedure that follows the principles of surgical asepsis, and probably due to the prophylactic antibiotherapy, justified by placement of implants and duration of surgery, since, in a study of 808 dogs that underwent TPLO surgery, it was shown that dogs that did not receive prophylactic antibiotherapy were 4 times more likely to develop surgical site infection than those receiving appropriate prophylactic antibiotics (Frey et al., 2010). The use of prophylactic antibiotics and adequate timing for their administration allied to the strict appropriate aseptic technique involving patient preparation, preparation of the surgical team, aseptic surgical technique and postoperative care, most likely contributed positively for such low rate of infection/osteomyelitis in the studied cases. Also, the length of anaesthesia is a risk factor for postoperative infection (Nicholson, Beal & Shofer, 2002; Eugster et al., 2004; Owen et al. 2009). However, in the present study such correlation could not be established due to the scarce number of infections and to the fact that anaesthesia duration was not recorded for each case. Still, an average of 2.5 hours was estimated for total anaesthesia time.

Fibular fractures are not common but may occur intraoperatively during manipulation of the ends of the tibia following ostectomy or while drilling the holes for the screws. In our case series, only one fibular fracture was reported, resulting in a rate of 0.7%, which is comparable to those reported following TPLO surgery that vary between 0.1% and 2.7% (Gatineau et al., 2011; Fitzpatrick & Solanno, 2010; Conkling et al., 2010; Duerr et al., 2008; Stauffer et al., 2006). This is a minor complication as it is easily managed conservatively, with exercise restriction being the most essential measure taking. The patient in question showed no clinical signs related to this condition. Bone healing was assessed on follow-up radiographs and there were no repercussions in the outcome.

Following surgical trauma, inflammation is considered a normal response. However, some patients develop bruising, marked erythema or swelling associated with the wound. In our study, oedema of the hock was reported in 3 cases and extensive bruising in one. It is important to mention that as the diagnosis is based on physical examination findings, it is subjective. Bruising can sometimes result from excessive surgical trauma. Some postoperative swelling around the surgical incision is often seen. When there is an excessive presence of fluid in the surgical incision after surgery of the stifle, it tends to move distally down the limb and accumulate in the hock because of gravity, leading to oedema or swelling of the hock. This may be associated to excessive surgical trauma, undermining of skin or excessive animal movement postoperatively. Generally, this is a minor complication, which resolves easily, not requiring

specific treatment unless it progresses to wound discharge, infection or dehiscence. Pain associated with the inflammation can be managed with analgesic drugs, massage and cold compression, which may improve significantly the clinical signs. Such measures were implemented in the discussed cases having resolved the clinical signs within one to two weeks. The obtained rate of 3.45% is comparable to the previously reported rates of incisional oedema, hematoma, bruising or drainage following TPLO procedure which vary from 0.7% to 13.3% (Garnett & Daye, 2014; Nelson et al., 2013; Cook et al., 2010; Duerr et al., 2008).

There were 2 cases of broken drill-bits. Surgical drill-bits are biologically inert materials, which means broken portions may be left in situ without causing any concern. However, when in contact with an implant, micromotion can generate wear particles which, if too large to be digested by the host's immune system, may elicit an inflammatory response resulting in osteolysis (Bertollo & Walsh, 2011). Both reported cases in the present study had further radiographic evaluation to ensure that migration was not occurring and to confirm there was no contact between the drill-bit and the implants.

The overall complication rate in this case series was 18.6% (27/145), which is comparable to previously published overall complication rates of 18.8% following TPLO procedure (Stauffer et al., 2006). However, in several similar retrospective studies, the reported complication rates following TPLO surgery were significantly higher, varying from 25% to 28% (Priddy et al., 2003; Pacchiana et al., 2003) as well as that reported following CWO procedure of 31.7% (Kuan et al., 2009). However, more recent retrospective studies, where a significantly higher number of cases of TPLOs were analysed, reported complication rates varying from 9.7% to 11.4% (Gatineau et al., 2011; Fitzpatrick & Solano, 2010; Coletti et al., 2014), which are considerably lower than that reported in the present study. However, in those studies only TPLOs performed by surgeons who had completed at least 100 procedures prior to the beginning of the study period were included, whereas in our study the adoption of such criteria was not feasible due to the limited number of cases available.

On the other hand, if we compare the rate of complications requiring second surgical intervention, the scenario is slightly different. Previously reported rates vary from 3.1% to 6.6% following TPLO (Coletti et al., 2014; Gatineau et al., 2011; Pacchiana et al., 2003; Fitzpatrick & Solano, 2010) and consist of 12.33% following CWO (Kuan et al., 2009), whereas in our case series major complications occurred in 3.4% of the cases. Therefore, regarding complications that required second surgical intervention, the rate obtained in our study is comparable to the most recent ones reported following TPLO surgery.

The retrospective nature of this study was its main limitation. Meaning that it was not possible to identify potential risk factors for complications as it would be in a prospective study. Also, a standardized report was not kept and some parameters were not mentioned in all patients' clinical records that were analysed. Such parameters included degree of CrCL damage, presence of meniscal injury and its management, preoperative TPA and radiographic follow-up. The absence of such parameters in some of the clinical records and the small number of complications reported did not allow further analysis of the data such as correlations between events that could have been studied otherwise as, for example, the risk of subsequent meniscal injury when no debridement nor meniscal release is performed in an intact meniscus at time of CWO surgery or if a correlation between pre-operative TPA and the occurrence of complications could be established. Also, follow-up radiographs were not available for all 145 cases, but all dogs were included in the statistics to assess for complications that weren't visible radiographically. Therefore, the rate of implant failure or loosening should be 4.5% (5/110). However, most of the previous similar studies did not take this aspect into consideration, hence, these corrected rates were not used to make comparisons between studies. In regards to degree of CrCL rupture, presence of meniscal injury, its management and preoperative TPA, frequencies were adjusted to the number of cases with available data for each parameter.

The patients were examined by various veterinary surgeons on follow-up appointments. This may have affected the results as the diagnosis of some of the complications considered have a subjective component for being based on clinical signs and physical examination findings. Surgical wound infections may have been particularly influenced by this factor as all those cases of suspected infections that were given empiric antibiotic treatment were included in the statistics despite further confirmation by bacterial culture. Similarly, assessment of excessive oedema or bruising may vary between observers, consequently, affecting the significance of the related values.

In contrast, radiographic follow-up was always performed by the same surgeon, who also performed the CWOs, which reduces the variables that can affect the radiographic evaluation, particularly regarding progression of OA and bone healing.

Outcome was not objectively evaluated due to the retrospective nature of this study. However, clinical records included information on overall patient's improvement following surgery, limb range of motion and owner's satisfaction. Amongst the 145 cases, only 3 cases that were later presented with mild lameness, lacked information with regards to progression of the lameness or achievement of full function due to absence of further records. However, this only represents

2% of our sample, and so 98% of the patients showed significant improvement or recovered full limb function, which is consistent with a good to excellent outcome.

Although there was only one veterinary surgeon performing the surgeries, all cases were included since he first started using this technique, therefore, his degree of experience varied throughout time. It is important to mention that all major complications occurred in between the first 50 CWOs that the surgeon performed, indicating being on an early phase of the learning curve.

Both CWO and TPLO procedure achieve the acceptable geometric and functional properties of reducing the TPA (Hildreth, Marcellin-Little, Roe & Harrysson, 2006). Potential advantages of the CWO procedure include technical simplicity as it does not require specialised equipment and has no copyright restrictions. Also, whereas TPLO is not recommended for dogs under 8 to 9 months of age due to potential injury to the proximal tibial physis, CWO can be performed in young dogs prior to closure of the proximal tibial physis. Regarding postoperative complications, some that have been associated with TPLO procedure such as tibial tuberosity and patellar fractures and patellar tendon swelling, are not seen following CWO surgery (Stauffer et al., 2006; Pacchiana et al., 2003; Kergosien et al., 2004). Nevertheless, CWO is a technically demanding surgery, and so, its potential for complications is high.

As has been previously reported, disadvantages associated with CWO procedure may include higher complication rate, discrepancy in proximal and distal osteotomy fragment cross-sectional area, bending and occasional fracture of the fibula, sub-optimal bone-implant construct stability, insufficient plateau rotation and conformational alteration of the surgical limb (Holsworth, 2004). If a large wedge is removed, it can shorten the tibia cranially and alter the femoropatellar joint, lowering the patella in relation to the femur, leading to hyperextension of the stifle joint (Corr & Brown, 2007), identified through kinematic gait analysis during the swing phase and at paw contact but not at stance phase (Lee et al., 2007). However, later studies have shown similar outcomes and complication rates for both CWO and TPLO procedures (Oxley et al., 2013; Corr & Brown, 2007).

V. CONCLUSION

CrCL disease is the leading cause of pelvic limb lameness in the dog (Hayashi, Manley & Muir, 2004) resulting in stifle joint instability which in turn results in development of progressive OA and, in some cases, meniscal disease (Kim et al., 2008; Fitzpatrick & Solano, 2010). So far, no specific surgical technique has proven to be the most efficient considering patient's recovery time, limb function outcome and progression of DJD. However, greater emphasis has been given to dynamic stabilization techniques bearing in mind their good long-term outcomes. These techniques are designed to neutralise the cranial tibial thrust force that is seen under weight-bearing conditions by compressive and muscular forces acting on the sloped tibial plateau when there is failure of the CrCL. This way, stability of the stifle is achieved dynamically during the stance phase of the gait (Slocum & Slocum, 1998). Although the techniques routinely performed for correction of CrCL-deficient stifle have been generally perceived to be successful, progression of OA and subsequent meniscal injury occur (Kim, Pozzi & Kowaleski, 2009) along with other potential complications. Efforts have been made to improve surgical technique and postoperative management in an attempt to reduce complication occurrence but it is sensible that the most effective strategies to prevent complications include cautious surgical planning, detailed application of the technique and excellent client education before and after surgery, regardless of the technique used.

In this study we described the surgical technique of the CWO surgery for correction of the CrCL-deficient stifle and analysed the intra- and postoperative complications associated with the procedure.

Out of 145 CWO procedures evaluated, the overall complication rate was 18.6%. Complications occurred either in the short- and long-term period. Minor complications were reported in 15.2% of cases, representing 81.5% of all complications. Complications requiring revision surgery occurred in 3.4% of the cases, which is comparable with the rates reported following TPLO procedure in the most recent studies, and included subsequent meniscal injury, implant failure and infection. Surgical wound infection was the most common complication encountered, followed by oedema and bruising around the surgical area. All five major complications resulted from cases of the first 50 procedures performed by the surgeon, which obviously reflects the learning curve associated to the surgical technique.

Based on the data from this study, we concluded that a reasonably low rate of complications can be expected following CWO procedures when performed by surgeons experienced with the surgical technique. Although there were some limitations in the design of this study, we hope

this data can be considered able to assist the Veterinary orthopaedic surgeons in selection of a technique to repair the CrCL-deficient stifle. However, results will likely depend upon surgeon's experience as has been suggested in the present study.

REFERENCES

- Alm, A. & Strömberg, B. (1974). Vascular anatomy of the patellar and cruciate ligaments. A microangiographic and histologic investigation in the dog. *Acta Chir Scand Suppl*, 445, 25-35.
- Anderson C. C., Tomlinson J. L., Daly W. R., Carson W. L., Payne J. T. & Wagner-Mann C. C. (1998). Biomechanical evaluation of a crimp clamp system for loop fixation of monofilament nylon leader material used for stabilization of the canine stifle joint. *Veterinary Surgery*, 27, 533–539.
- Anderst, W. J. & Tashman, S. (2009). The association between velocity of the center of closest proximity on subchondral bones and osteoarthritis progression. *J Orthop Res*, 27, 71-77.
- Apelt, D., Pozzi, A., Marcellin-Little, D. J. & Kowaleski, M. P. (2010). Effect of cranial tibial closing wedge angle on tibial subluxation: an ex vivo study. *Vet Surg*, 39(4), 454-459.
- Aragon, C. & Budsberg, S. (2005). Applications of Evidence-Based Medicine: Cranial Cruciate Ligament Injury Repair in the Dog. *Veterinary Surgery*, 34(2), 93-98.
- Arnault, F., Cauvin, E., Viguier, E., Kraft, E., Sonet, J. & Carozzo, C. (2009). Diagnostic value of ultrasonography to assess stifle lesions in dogs after cranial cruciate ligament rupture: 13 cases. *Vet Comp Orthop Traumatol*. 22(6), 479-85.
- Arnoczky, S. P. & Marshall, J. L. (1977). The cruciate ligaments of the canine stifle: an anatomical and functional analysis. *American Journal of Veterinary Research*, 38(11), 1807-1814.
- Arnoczky, S. P. (1980). Surgery of the stifle - The cruciate ligaments (Part I). *Comp Cont Ed*, 2, 106-116.
- Arnoczky, S. P. (1988). The cruciate ligaments: the enigma of the canine stifle. *J Small Anim Pract*, 29, 71-90.
- Arnoczky, S. P. (1993). Pathomechanics of cruciate ligament and meniscal injuries. In M. J. Bojrab (Ed.), *Disease mechanisms in small animal surgery*, (2nd ed.). (pp. 764-776). Lea Febiger, Philadelphia.
- Arnoczky, S. P. (1993). Pathomechanics of cruciate ligaments and meniscal injuries. In M. J. Bojrab (Ed.), *Disease Mechanisms in Small Animal Surgery* (2nd ed.). (pp. 764-776). Lea & Febiger, Philadelphia.
- Arnoczky, S. P., Rubin, R. M. & Marshall, J. L. (1979). Microvasculature of the cruciate ligaments and its response to injury. An experimental study in dogs. *The Journal of Bone & Joint Surgery*, 61(8), 1221-1229.
- Arnoczky, S. P., Tarvin, G. B. & Marshall, J. L. (1982). Anterior cruciate ligament replacement using patellar tendon. An evaluation of graft revascularization in the dog. *The Journal of Bone and Joint Surgery*. American Volume, 64(2), 217-224.
- Arruda, A., Muzzi, L., Muzzi, R., Lacreta Júnior, A., Oberlender, G. & Silva, W. (2015). Comparison of the proximal tibial angles between Labrador Retrievers and other dog breeds with and without cranial cruciate ligament rupture. *Arquivo Brasileiro de Medicina Veterinária e Zootecnia*, 67(5), 1254-1262.
- Ata, A., Lee, J., Bestle, S. L., Desemone, J. & Stain, S. C. (2010). Postoperative hyperglycemia and surgical site infection in general surgery patients. *Archives of Surgery*, 145 (9), 858-864.

- Atherton, M. J. & Arthurs, G. (2012). Osteosarcoma of the tibia 6 years after tibial plateau leveling osteotomy. *Journal of the American Animal Hospital Association*, 48, 188-193.
- Au, K. K., Gordon-Evans, W. J., Dunning, D., O'Dell-Anderson, K. J., Knap, K. E., Griffon, D. & Johnson, A. L. (2009). Comparison of short and long term function and radiographic osteoarthritis in dogs with naturally occurring cranial cruciate ligament injury receiving postoperative physical therapy and tibial plateau leveling osteotomy or lateral fabellar suture. *Proceedings of the Veterinary Orthopedic Society Annual Conference*. Steamboat Springs, CO, 14.
- Austin, B., Montgomery R. D., Wright J., Bellah, J. R. & Tonks, C. (2007). Evaluation of three approaches to meniscal release. *Vet Comp Orthop Traumatol*, 20 (2), 92-97.
- Axelrad, T. W. & Einhorn, T. A. (2011). Use of clinical assessment tools in the evaluation of fracture healing. *Injury*, 42, 301-305.
- Bailey, C., Smith, B. & Black, A. (2007). Geometric implications of the tibial wedge osteotomy for the treatment of cranial cruciate ligament disease in dogs. *Veterinary and Comparative Orthopaedics and Traumatology*.
- Baird, A., Carter, S., Innes, J., Ollier, W. & Short, A. (2014). Genetic basis of cranial cruciate ligament rupture (CCLR) in dogs. *Connective Tissue Research*, 55(4), 275-281.
- Barrett, E., Barr, F., Owen, M. & Bradley, K. (2009). A retrospective study of the MRI findings in 18 dogs with stifle injuries. *Journal of Small Animal Practice*, 50(9), 448-455.
- Beal, M., Brown, D. & Shofer, F. (2000). The Effects of Perioperative Hypothermia and the Duration of Anesthesia on Postoperative Wound Infection Rate in Clean Wounds: A Retrospective Study. *Veterinary Surgery*, 29(2), 123-127.
- Beale, B. S. & Hulse, D. A., (2010). Arthroscopy versus Arthrotomy for Surgical Treatment. In P. Muir (Ed.), *Advances in canine cranial cruciate ligament*. (1st ed.). (pp. 145-159). Wiley-Blackwell.
- Beale, B. S., Hulse, D. A., Schulz, K. S. & Whitney, W.O. (2003). *Small Animal Arthroscopy*. Philadelphia: W.B. Saunders, 117-157.
- Bennett, D. & May, C. (1991). Meniscal damage associated with cruciate disease in the dog. *J Small Animal Practice*, 32(3), 111-117.
- Bennett, D., Tennant, B., Lewis, D. G., Baughan, J., May, C. & Carter, S. (1988) A reappraisal of anterior cruciate disease in the dog. *Journal of Small Animal Practice*, 29, 275.
- Bergh, M. S., Rajala-Schultz, P. & Johnson, K. A. (2008). Risk factors for tibial tuberosity fracture after tibial plateau leveling osteotomy in dogs. *Veterinary Surgery*, 37 (4), 374-382.
- Bergh, M.S., Peirone, B. (2012). Complications of tibial plateau levelling osteotomy in dogs. *Veterinary and Comparative Orthopaedics and Traumatology* 25 (5):349-358.
- Bertollo, N. & Walsh, W. R. (2011). Drilling of Bone: Practicality, Limitations and Complications Associated with Surgical Drill-Bits. In V. Klika (Ed.) *Biomechanics in Applications*, ISBN: 978-953-307-969-1, InTech.
- Blond, L., Thrall, D. E., ROE, S. C., Chailleux, N. & Robertson, I. D. (2008). Diagnostic accuracy of magnetic resonance imaging for meniscal tears in dogs affected with naturally occurring cranial cruciate ligament rupture. *Veterinary Radiology and Ultrasound*, 49, 425-431.
- Boekhout, C. & Cross, A. (2012). Incidence of Transcortical Tibial Fractures with Self-Tapping and Non-Self-Tapping Screws in a Canine TPLO Model. *Veterinary Surgery*, 41(7), 898-901.

- Böttcher, P., Winkels, P. & Oechtering, G. (2009). A novel pin distraction device for arthroscopic assessment of the medial meniscus in dogs. *Veterinary Surgery*, 38, 595-600.
- Boudrieau, R. & Kowaleski, M. (2009). Risk Factors for Tibial Tuberosity Fracture after Tibial Plateau Leveling Osteotomy in Dogs. *Veterinary Surgery*, 38(3), 426-426.
- Boudrieau, R.J., McCarthy, R.J. & Sisson, Jr. R.D. (2005). Sarcoma of the proximal portion of the tibia in a dog 5.5 years after tibial plateau leveling osteotomy. *Journal of the American Veterinary Medical Association*, 227 (10), 1613-1617.
- Boyd, D. J., Miller, C. W., Etue, S. M. & Monteith, G. (2007). Radiographic and functional evaluation of dogs at least 1 year after tibial plateau leveling osteotomy. *Canadian Veterinary Journal*, 48, 392-396.
- Brandt, K. (1987). Effects of nonsteroidal anti-inflammatory drugs on chondrocyte metabolism in vitro and in vivo. *The American Journal of Medicine*, 83(5), 29-34.
- Brown, D. C., Conzemius, M. G., Shofer, F. & Swann, H. (1997). Epidemiologic evaluation of postoperative wound infections in dogs and cats. *Journal of the American Veterinary Medical Association*, 210, 1302-1306.
- Buote, N., Fusco, J. & Radasch, R. (2009). Age, tibial plateau angle, sex, and weight as risk factors for contralateral rupture of the cranial cruciate ligament in Labradors. *Vet Surgery*, 38, 481-489.
- Cabrera, S. Y., Owen, T. J., Mueller M. G. & Kass, P. H. (2008). Comparison of tibial plateau angles in dogs with unilateral versus bilateral cranial cruciate ligament rupture: 150 cases (2000 – 2006). *J Am Vet Med Assoc*, 232, 889-892.
- Caldwell, F. (2015). Postoperative care of the cruciate patient. In BSAVA Congress Scientific Proceedings 2015, April, Birmingham, UK.
- Calvo, I., Aisa, J., Chase, D., Garcia-Fernandez, P., San Roman, F. & Bennett, D. (2014). Tibial tuberosity fracture as a complication of tibial tuberosity advancement. *Veterinary and Comparative Orthopaedics and Traumatology*, 27 (2), 148-154.
- Carobbi, B. & Ness, M. (2009). Preliminary study evaluating tests used to diagnose canine cranial cruciate ligament failure. *Journal of Small Animal Practice*, 50(5), 224-226.
- Casale, S. A. & McCarthy, R. J. (2009). Complications associated with lateral fabellotibial suture surgery for cranial cruciate ligament injury in dogs: 363 cases (1997-2005). *J Am Vet Med Assoc*, 234(2), 229-235.
- Case, J. B., Hulse, D., Kerwin, S. C. & Peycke, L. E. (2008). Meniscal injury following initial cranial cruciate ligament stabilization surgery in 26 dogs (29 stifles). *Vet Comp Orthop Traumatol*, 21, 365-367.
- Caylor, K., B., Zumpano, C. A., Evans, L. M. & Moore, R. W. (2001). Intra- and interobserver measurement variability of tibial plateau slope from lateral radiographs in dogs. *Journal of the American Animal Hospital Association*, 37(3), 263-268.
- Chauvet, A. E., Johnson, A. L., Pijanowski, G. J., Homco, L. & Smith, R. D. (1996). Evaluation of fibular head transposition, lateral fabellar suture, and conservative treatment of cranial cruciate ligament rupture in large dogs: A retrospective study. *J Am Anim Hosp Assoc*, 32, 247-255.

- Christopher, S., Beetem, J. & Cook, J. (2013). Comparison of Long-Term Outcomes Associated With Three Surgical Techniques for Treatment of Cranial Cruciate Ligament Disease in Dogs. *Veterinary Surgery*, 42(3), 329-334.
- Chrysis, D., Zaman, F., Chagin, A. S., Takigawa, M. & Savendahl, L. (2005). Dexamethasone induces apoptosis in proliferative chondrocytes through activation of caspases and suppression of the Akt-phosphatidylinositol 3'-kinase signaling pathway. *Endocrinology*, 146(3), 1391-1397.
- Coletti, T. J., Anderson, M., Gorse, M. J. & Madsen, R. (2014). Complications associated with tibial plateau levelling osteotomy: A retrospective of 1519 procedures. *Can Vet J*, 55(3), 249-254.
- Conkling, A. L., Fagin & B., Daye, R. M. (2010). Comparison of tibial plateau angle changes after tibial plateau levelling osteotomy fixation with conventional or locking screw technology. *Vet Surg*, 39(4), 475-481.
- Conzemius, M. G., Evans, R. B., Besancon, M. F., Gordon, W. J., Horstman, C. L., Hoefle, W. D., Nieves, M. A. & Wagner, S. D. (2005). Effect of surgical technique on limb function after surgery for rupture of the cranial cruciate ligament in dogs. *Journal of the American Veterinary Medical Association*, 226(2), 232-236.
- Cook, J. L. (2010). Extracapsular Stabilization. In P. Muir (Ed.) *Advances in the canine cranial cruciate ligament* (1st ed.). (pp. 163-168). Wiley-Blackwell.
- Cook, J. L., Evans, R., Conzemius, M. G., Lascelles, B. D., McIlwraith, C. W., Pozzi, A., Clegg, P., Innes, J., Schulz, K., Houlton, J., Fortier, L., Cross, A. R., Hayashi, K., Kapatkin, A., Brown, D. C. & Stewart, A. (2010). Proposed Definitions and Criteria for Reporting Time Frame, Outcome, and Complications for Clinical Orthopedic Studies in Veterinary Medicine. *Vet Surg*, 39(8), 905-908.
- Cook, J. L., Luther, J. K., Beetem, J., Karnes, J. & Cook, C. R. (2010). Clinical comparison of a novel extracapsular stabilization procedure and tibial plateau levelling osteotomy for treatment of cranial cruciate ligament deficiency in dogs. *Vet Surg*, 39, 315-323.
- Corr, S. (2009). Decision making in the management cruciate disease in dogs. *In Practice*, 31, 164-171.
- Corr, S. A. & Brown, C. (2007). A comparison of outcomes following tibial plateau levelling osteotomy and cranial tibial wedge osteotomy procedures. *Vet Comp Orthop Traumatol*, 20, 312-319.
- D'Anjou, M. A., Moreau, M., Troncy, E., Martel-Pelletier, J., Abram, F., Raynauld, J. P. & Pelletier, J. P. (2008). Osteophytosis, subchondral bone sclerosis, joint effusion and soft tissue thickening in canine experimental stifle osteoarthritis: comparison between 1.5 T magnetic resonance imaging and computed radiography. *Vet Surgery*, 37(2), 166-177.
- Darouiche, R. (2004). Treatment of Infections Associated with Surgical Implants. *New England Journal of Medicine*, 350(14), 1422-1429.
- de Bruin, T., de Rooster, H., van Bree, H. & Cox, E. (2007a) Evaluation of anticollagen type I antibody titers in synovial fluid of both stifle joints and the left shoulder joint of dogs with unilateral cranial cruciate disease. *Am J Vet Res*, 68, 283-289.
- de Rooster, H., Van Ryssen, B. & van Bree, H. (1998). Diagnosis of cranial cruciate ligament injury in dogs by tibial compression radiography. *Vet Rec*, 142(14), 366-8.

- DeAngelis, M. & Lau, R. E. (1970). A lateral retinacular imbrication technique for the surgical correction of anterior cruciate ligament rupture in the dog. *Journal of the American Veterinary Medical Association*, 157(1), 79-84.
- Dearmin, M. G., Trumble, T. N., Garcia, A., Chambers, J. N. & Budsberg, S. C. (2014). Chondroprotective effects of zoledronic acid on articular cartilage in dogs with experimentally induced osteoarthritis. *American Journal of Veterinary Research*, 75(6), 594-594.
- DeCamp, C. E., Riggs, C. M., Olivier, N. B., Hauptman, J. G., Hottinger, H. A. & Soutas-Little, R. W. (1996). Kinematic evaluation of gait in dogs with cranial cruciate ligament rupture. *Am J Vet Res*, 57, 120-126.
- Dejardin, (2003). Tibial Plateau Levelling Osteotomy. In D. H. Slatter (Ed.), *Textbook of Small Animal Surgery*. (3rd ed.). (pp. 2133-2143). Saunders.
- Denny, H. R. & Butterworth, S. J. (2000). The Stifle. In H. R. Denny & J. Butterworth (Ed.), *A Guide to Canine and Feline Orthopaedic Surgery*. (4th ed.). (pp. 512-553). Oxford, Blackwell Science Ltd
- Dickinson, C. R., & Nunamaker, D. M. (1977). Repair of ruptured anterior cruciate ligament in the dog: experience in 101 cases, using a modified fascia strip technique. *Journal of the American Veterinary Medical Association*, 170(8), 827-830.
- Dieppe, P. A., Cushnaghan, J. & Shepstone, L. (1997). The Bristol 'OA500' study: progression of osteoarthritis (OA) over 3 years and the relationship between clinical and radiographic changes at the knee joint. *Osteoarthritis Cartilage*, 5(2), 87-97.
- Dillon, D. E., Gordon-Evans, W. J., Griffon, D. J., Knap, K. M., Bubb, C. L. & Evans, R. B. (2014). Risk factors and diagnostic accuracy of clinical findings for meniscal disease in dogs with cranial cruciate ligament disease. *Veterinary Surgery*, 43(4), 446-450.
- Donlan, R. (2001). Biofilm Formation: A Clinically Relevant Microbiological Process. *Clinical Infectious Diseases*, 33(8), 1387-1392.
- Doverspike, M., Vasseur, P. B., Harb, M. F. & Walls, C. M. (1993). Contralateral cranial cruciate ligament rupture: Incidence in 114 dogs. *J Am Anim Hosp Assoc*, 29, 167-170.
- Duerr, F. M., Duncan, C. G., Savicky, R. S., Park, R. D., Egger, E. L. & Palmer, R. H. (2007). Risk factors for excessive tibial plateau angle in large - breed dogs with cranial cruciate ligament disease. *J Am Vet Med Assoc*, 231, 1688-1691.
- Dupuis, J. & Harari, J. (1993). Cruciate ligament and meniscal injuries in dogs. *Compendium of Continuing Education for the Practising Veterinarian*, 15(2), 215-229.
- Duval, J. M., Budsberg, S. C., Flo, G. L. & Sammarco, J. L. (1999). Breed, sex, and body weight as risk factors for rupture of the cranial cruciate ligament in young dogs. *J Am Vet Med Assoc*, 215, 811-814.
- Edge-Hughes, L. & Nicholson, H. (2007). Canine treatment and rehabilitation. In McGrwan, Goff & Stubbs (Eds.), *Animal Physiotherapy Assessment, Treatment and Rehabilitation of Animals* (1st ed.). (pp. 206-237). Blackwell Publishing, Ames, Iowa.
- Ekstein, M. & Weinbroum, A. (2011). Immediate Postoperative Pain in Orthopaedic Patients Is More Intense and Requires More Analgesia than in Post-Laparotomy Patients. *Pain Med*, 12(2), 308-313.
- Eriksson, R. A., Albrektsson, T. & Magnusson, B. (1984). Assessment of bone viability after heat trauma: A histological, histochemical and vital microscopic study in the rabbit.

- Scandinavian Journal of Plastic and Reconstructive Surgery and Hand Surgery*, 18(3), 261-268.
- Etter, S. W., Ragetly, G. R., Bennett, R. A. & Schaeffer, D. J. (2013) Effect of using triclosan-impregnated suture for incisional closure on surgical infection and inflammation following tibial plateau levelling osteotomy in dogs. *Journal of the American Veterinary Medical Association*, 242 (3), 355-358.
- Eugster, S., Schawalder, P., Gaschen, F. & Boerlin, P. (2004). A Prospective Study of Postoperative Surgical Site Infections in Dogs and Cats. *Veterinary Surgery*, 33(5), 542-550.
- Evans, H. E. & Hermanson, J. W. (1993). The skeleton, arthrology, the muscular system. In H. E. Evans (Ed.), *Miller's anatomy of the dog* (3rd ed.). (pp. 122-384). W. B. Saunders, Philadelphia, PA.
- Fettig, A. A., Rand, W. M., Sato, A. F., Solano, M., McCarthy, R. & Boudrieau, R. (2003). Observer variability of tibial plateau slope measurement in 40 dogs with cranial cruciate ligament-deficient stifle joints. *Veterinary Surgery*, 32(5), 471-478.
- Fine, D. & Tobias, A. (2007). Cardiovascular Device Infections in Dogs: Report of 8 Cases and Review of the Literature. *Journal of Veterinary Internal Medicine*, 21(6), 1265-1271.
- Fitzpatrick, N. & Solano, M. (2010). Predictive Variables for Complications after TPLO with Stifle Inspection by Arthrotomy in 1000 Consecutive Dogs. *Veterinary Surgery*, 39(4), 460-474.
- Flo, G. L. & DeYoung, D. (1978). Meniscal injuries and medial meniscectomy in the canine stifle. *J Am Anim Hosp Assoc*, 14, 683-689.
- Franklin, S. P., Gilley, R. S. & Palmer, R. H. (2010). Meniscal injury in dogs with cranial cruciate ligament rupture. *Compend Contin Educ Vet*, 32, E1-E11
- Frey, T. N., Hoelzler, M. G., Scavelli, T. D., Fulcher, R. P. & Bastian, R. P. (2010). Risk factors for surgical site infection-inflammation in dogs undergoing surgery for rupture of the cranial cruciate ligament: 902 cases (2005-2006). *Journal of the American Veterinary*, 236(1), 88-94.
- Gallagher, A. & Mertens, W. (2012). Implant Removal Rate from Infection after Tibial Plateau Leveling Osteotomy in Dogs. *Veterinary Surgery*, 41(6), 705-711.
- Galloway, R. H. & Lester, S. J. (1995). Histopathological evaluation of canine stifle joint synovial membrane collected at the time of repair of cranial cruciate ligament rupture. *J Am Anim Hosp Assoc*, 31, 289-294.
- Gambardella, P. C., Wallace, L. J. & Cassidy, F. (1981). Lateral suture technique for management of anterior cruciate ligament rupture in dogs: a retrospective study. *J Am Anim Hosp Assoc*, 17, 33-38,
- Garnett, S. D. & Daye, R. M. (2014). Short-term complications associated with TPLO in dogs using 2.0 and 2.7 mm plates. *J Am Anim Hosp Assoc*, 50(6), 396-404.
- Gatineau, M., Dupuis, J., Planté, J. & Moreau, M. (2011). Retrospective study of 476 tibial plateau levelling osteotomy procedures. Rate of subsequent "pivot shift," meniscal tear and other complications. *Veterinary and Comparative Orthopaedics and Traumatology*, 24 (5), 333-341.
- Gielen, I., Van Caelenberg, A. & van Bree, H. (2003). Computed tomography (CT) in small animals: Part 1 Technical aspects. *Vlaams Diergeneeskundig Tijdschrift*, 72, 158-167.

- Gnudi, G. & Bertoni, G. (2001). Echography examination of the stifle joint affected by cranial cruciate ligament rupture in the dog. *Vet Radiol Ultrasound*, 42, 266-270.
- Gordon, W. J., Besancon, M. F., Conzemius, M. G., Miles, K. G., Kapatkin, A. S. & Culp, W. T. N. (2003). Frequency of posttraumatic osteoarthritis in dogs after repair of a humeral condylar fracture. *Veterinary and Comparative Orthopaedics and Traumatology*, 16, 1-5.
- Gordon, W., Conzemius, M., Riedesel, E., Besancon, M., Evans, R., Wilke, V. & Ritter, M. (2003). The relationship between limb function and radiographic osteoarthrosis in dogs with stifle osteoarthrosis. *Veterinary Surgery*, 32(5), 451-454.
- Gordon-Evans, W., Griffon, D., Bubb, C., Knap, K., Sullivan, M. & Evans, R. (2013). Comparison of lateral fabellar suture and tibial plateau levelling osteotomy techniques for treatment of dogs with cranial cruciate ligament disease. *Journal of the American Veterinary Medical Association*, 243(5), 675-680.
- Griffon, (2016). Complications associated with cranial cruciate ligament repair. In D. Griffon, A. Hamaide (Ed.), *Complications in Small Animal Surgery* (1st ed.). (pp. 867-888). Wiley Blackwell.
- Griffon, D. & Hamaide, A. (2016). *Complications in small animal surgery*. (1st ed.). Wiley-Blackwell
- Gristina, A. G. (1987). Biomaterial-centered infection: microbial adhesion versus tissue integration. *Science*, 237(4822), 1588-1595.
- Guthrie, J., Keeley, B., Maddock, E., Bright, S. & May, C. (2012). Effect of signalment on the presentation of canine patients suffering from cranial cruciate ligament disease. *Journal of Small Animal Practice*, 53(5), 273-277.
- Han, S., Cheon, H., Cho, H., Kim, J., Kang, J. H., Yang, M. P., Lee, Y., Lee, H. & Chang, D. (2008). Evaluation of partial cranial cruciate ligament rupture with positive contrast computed tomographic arthrography in dogs. *Journal of Veterinary Science*, 9(4), 395-400.
- Harari, J. (1993). Caudal cruciate ligament injury. *Vet Clin North Am Small Anim Pract*, 23, 821-829.
- Harasen, G. (2008). Canine cranial cruciate ligament rupture in profile: 2002 – 2007. *Can Vet J*, 49, 193-194.
- Harasen, G. L. & Simko, E. (2008). Histiocytic sarcoma of the stifle in a dog with cranial cruciate ligament failure and TPLO treatment. *Veterinary and Comparative Orthopaedics and Traumatology*, 21(4), 375-377.
- Hayashi, K., Frank, J. D., Dubinsky, C., Zhengling, H., Markel, M. D., Manley, P. A. & Muir, P. (2003). Histologic changes in ruptured canine cranial cruciate ligament. *Vet Surg*, 32, 269-277 .
- Hayashi, K., Manley, P. & Muir, P. (2004). Cranial Cruciate Ligament Pathophysiology in Dogs with Cruciate Disease: A Review. *Journal of the American Animal Hospital Association*, 40(5), 385-390.
- Hayda, R. A., Brighton, C. T., Esterhai, J. L. (1998). Pathophysiology of delayed healing. *Clinical Orthopaedics and Related Research*, 355 (Suppl.), S32.
- Hayes, G. M., Granger, N., Langley-Hobbs, S. J., & Jeffery, N. D. (2013). Abnormal reflex activation of hamstring muscles in dogs with cranial cruciate ligament rupture. *The Veterinary Journal*, 196(3), 345-350.

- Hayes, G. M., Reynolds, D., Moens, N. M. M., Singh, A., Oblak, M., Gibson, T. W. G., Brisson, B. A., Nazarali, A. & Dewey, C. (2014). Investigation of Incidence and Risk Factors for Surgical Glove Perforation in Small Animal Surgery. *Veterinary Surgery*, 43(4), 400-404.
- Heffron, L. E. & Campbell, J. R. (1978). Morphology, histology and functional anatomy of the canine cranial cruciate ligament. *Vet Rec*, 102, 280-283.
- Hegemann, N., Wondimu, A., Kohn, B., Brunberg, L. & Schmidt, M. F. (2005). Cytokine profile in canine immune-mediated polyarthritis and osteoarthritis. *Vet Comp Orthop Traumatol*, 18(2), 67-72.
- Henderson, R. A. & Milton, J. L. (1978). The tibial compression mechanism: a diagnostic aid in stifle injuries. *J Am Anim Hosp Assoc*, 14, 474-479.
- Hildreth, B. E., Marcellin-Little, D. J., Roe, S. C., & Harrysson, O. L. A. (2006). In vitro evaluation of five canine tibial plateau levelling methods. *American journal of veterinary research*, 67(4), 693-700.
- Hirshenson, M. S., Krotscheck, U., Thompson, M. S., Knapp-Hoch, H. M., Jay-Silva, A. R., McConkey, M., Bliss, S. P., Todhunter, R. & Mohammed, H. O. (2012). Evaluation of complications and short-term outcome after unilateral or single-session bilateral tibial tuberosity advancement for cranial cruciate rupture in dogs. *Veterinary and Comparative Orthopaedics and Traumatology*, 25(5), 402-409.
- Hoffer, M. J., Griffon, D. J., Schaeffer, D. J., Johnson, A. L., Thomas, M. W. (2008) Clinical applications of demineralized bone matrix: a retrospective and case-matched study of 75 dogs. *Veterinary Surgery*, 37(7), 639-647.
- Holsworth, I. G. (2004). Clinical comparison of TPLO vs tibial closing wedge osteotomy. *Proceedings, 12th European Society of Veterinary Orthopaedics and Traumatology*, Munich, Germany, 62.
- Hossain, M. A., Park, J., Choi, S. H. & Kim G. (2008). Dexamethasone induces apoptosis in proliferative canine tendon cells and chondrocytes. *Vet Comp Orthop Traumatol*, 21, 337-342.
- Hulse, D. A., Michaelson, F., Johnson, C. & Abdelbaki, Y. Z. (1980). A technique for reconstruction of the anterior cruciate ligament in the dog: Preliminary report. *Vet Surg*, 4, 135-140.
- Hunt, J. R., Attenburrow, P. M., Slingsby, L. S. & Murrell, J. C. (2013). Comparison of premedication with buprenorphine or methadone with meloxicam for postoperative analgesia in dogs undergoing orthopaedic surgery. *J Small Anim Pract*, 54(8), 418-24.
- Hurley, C. R., Hammer, D. L. & Shott, S. (2007). Progression of radiographic evidence of osteoarthritis following tibial plateau levelling osteotomy in dogs with cranial cruciate ligament rupture: 295 cases (2001-2005). *Journal of the American Veterinary Medical Association*, 230, 1674-1679.
- Jaeger, G. H. & Budsberg, S. C. (2010). Medical Therapy for Stifle Arthritis. In P. Muir (Ed.) *Advances In the Canine Cranial Cruciate Ligament* (1st ed.). (pp. 241-247). Wiley-Blackwell.
- Jerram, R. M., Walker, A. M. (2003). Cranial cruciate ligament injury in the dog: Pathophysiology, diagnosis and treatment. *N Z Vet J*, 51, 149-158.
- Johansson, H., Sjölander, P. & Sojka, P. (1991). A sensory role for the cruciate ligaments. *Clin Orthop Rel Res*, 268, 161-178.

- Johnson, A. L. & Hulse, D. A. (2002) Fundamentals of orthopedic surgery and fracture management. In T. W. Fossum (Ed.), *Small Animal Surgery* (2nd ed.). (pp. 821-900). ST. Louis: Mosby.
- Johnson, J. M. & Johnson, A. L. (1993). Cranial cruciate ligament rupture. Pathogenesis, diagnosis, and postoperative rehabilitation. *Vet Clin North Am Small Anim Pract*, 23(4), 717-33.
- Johnson, K. A., Francis, D. J., Manley, P. A., Chu, Q. & Caterson, B. (2004). Comparison of the effects of caudal pole hemi-meniscectomy and complete medial meniscectomy in the canine stifle joint. *Am J Vet Res*, 65, 1053-1060 .
- Johnson, K., Pozzi, A., Litsky, A., Field, J., Apelt, D. & Meadows, C. (2008). Pressure distributions on the medial tibial plateau after medial meniscal surgery and tibial plateau levelling osteotomy in dogs. *Veterinary and Comparative Orthopaedics and Traumatology*, 21(1), 8-14.
- Johnson, K., Vaughan, A., Derkay, C., Welch, J. C., Werner, A., Kuhn, M. A., Singletary, S. & Bondy, P. (2008). Microdebrider vs electrocautery: a comparison of tonsillar wound healing histopathology in a canine model. *Otolaryngol Head Neck Surg*, 138, 486-491.
- Kampf, G., Rudolf, M., Labadie, J. C. & Barrett, S. P. (2002). Spectrum of antimicrobial activity and user acceptability of the hand disinfectant agent Sterillium Gel. *J Hosp Infect*, 52(2), 141-7.
- Kergosien, D. H., Barnhart, M. D., Kees, C. E., Danielson, B. G., Brouman, J. D., DeHoff, W. D. & Schertel, E. R. (2004). Radiographic and clinical changes of the tibial tuberosity after tibial plateau levelling osteotomy. *Veterinary Surgery*, 33(5), 468-474.
- Kergosien, D. H., Barnhart, M. D., Kees, C. E., Danielson, B. G., Brouman, J. D., Dehoff, W. D. & Schertel, E. R., (2004). Radiographic and clinical changes of the tibial tuberosity after tibial plateau leveling osteotomy. *Vet Surg*, 33, 468-474.
- Kiefer, J. E., Langenbach, A., Boim, J., Gordon, S. & Marcellin-Little, D. J. (2015) Single-stage bilateral tibial tuberosity advancement for treatment of bilateral canine cranial cruciate ligament deficiency. *Vet Comp Orthop Traumatol*, 28, 215-219.
- Kim, S. E., Lewis, D. D. & Pozzi, A. (2012). Effect of tibial plateau levelling osteotomy on femorotibial subluxation: In vivo analysis during standing. *Vet Surg*, 41, 465-470.
- Kim, S. E., Pozzi, A., Banks, S. A., Conrad, B. & Lewis, D. D. (2009) Effect of tibial plateau levelling osteotomy on femorotibial contact mechanics and stifle kinematics. *Vet Surg*, 38, 33-39.
- Kim, S. E., Pozzi, A., Kowaleski, M. P. & Lewis, D. D. (2008). Tibial osteotomies for cranial cruciate ligament insufficiency in dogs. *Vet Surg*, 37(2), 111-125.
- Kivumbi, C. W. & Bennett, D. (1981). Arthroscopy of the canine stifle joint. *Veterinary Record*, 109, 241-249.
- Klein, W. & Kurze, V. (1986). Arthroscopic arthropathy: iatrogenic arthroscopic joint lesions in animals Arthroscopy. *The Journal of Arthroscopic & Related Surgery*, 2(3), 163-168.
- Kobayashi, S., Baba, H., Uchida, K., Negoro, K., Sato, M., Miyazaki, T, Nomura, E., Murakami, K., Shimizubata, M. & Meir, A. (2006). Microvascular system of the anterior cruciate ligament in dogs. *J. Orthop Res*, 24, 1509-1520.

- Korvick, D. L., Pijanowski, G. J. & Schaeffer, D. J. (1994). Three-dimensional kinematics of the intact and cranial cruciate ligament-deficient stifle of dogs. *J Biomech*, 27, 77-87.
- Kotnis, R., Halstead, J. & Hormbrey, P. (1999). Atraumatic bilateral Achilles tendon rupture: an association of systemic steroid treatment. *Emergency Medicine Journal*, 16(5), 378-379.
- Kowaleski, M. P. & McCarthy, R. J. (2004). Geometric analysis evaluating the effect of tibial plateau leveling osteotomy position on postoperative tibial plateau slope. *Veterinary Compendium of Orthopaedics and Traumatology*, 17, 30-34.
- Kowaleski, M. P., Apelt, D., Mattoon, J. S. & Litsky, A. S. (2005). The effect of tibial plateau levelling osteotomy position on cranial tibial subluxation: An in vitro study. *Vet Surg*, 34, 332-336.
- Kowaleski, M. P., Boudrieau, R. & Pozzi, A. (2012). Stifle joint, in K. Tobias & S. Johnston (Eds.), *Veterinary Surgery: Small Animal*. (pp. 973-979). Saunders Elsevier, St Louis, Missouri
- Kramer, M., Stengel, H., Gerwing, M., Schimke, E. & Sheppard, C. (1999). Sonography of the canine stifle. *Vet Radiol Ultrasound*, 40, 282-293.
- Kuan, S., Smith, B. & Black, A. (2009). Tibial wedge ostectomy: complications of 300 surgical procedures. *Australian Veterinary Journal*, 87(11), 438-444.
- Lafaver, S., Miller, N. A., Stubbs, W. P., Taylor, R. A. & Boudrieau, R. J. (2007). Tibial tuberosity advancement for stabilization of the canine cranial cruciate ligament-deficient stifle joint: surgical technique, early results, and complications in 101 dogs. *Veterinary Surgery*, 36(6), 573-586.
- Laitinen-Vapaavuori (2016). Surgical Wound Infections. In D. Griffon, A. Hamaide (Eds.), *Complications in Small Animal Surgery*, (1st ed.). (pp. 3-7). Wiley Blackwell.
- Lambert, C., Bianchi, E., Keroack, S., Genevois, J. P., Soldani, G. & Troncy, E. (2004) Reduced dosage of ketoprofen alone or with tramadol for long-term treatment of osteoarthritis in dogs. In Abstracts from the 8th World Congress of Veterinary Anesthesia, Knoxville. American College of Veterinary Anesthesiologists; 2003. p. 157.
- Lascalles, B. & Main, D. (2002). Surgical trauma and chronically painful conditions - within our comfort level but beyond theirs?. *Journal of the American Veterinary Medical Association*, 221(2), 215-222.
- Lascalles, B., Gaynor, J. S., Smith, E. S., Roe, S. C., Marcellin-Little, D. J., Davidson, G., Boland, E. & Carr, J. (2008). Amantadine in a multimodal analgesic regimen for alleviation of refractory osteoarthritis pain in dogs. *J Vet Intern Med*, 22, 53-59.
- Lazar, T. P., Berry, C. R., de Haan, J. J., Peck, J. N. & Correa, M. (2005). Long-term radiographic comparison of tibial plateau levelling osteotomy versus extracapsular stabilization for cranial cruciate ligament rupture in the dog. *Vet Surg*, 34, 133-141.
- Lee, J., Kim, G., Kim, J. & Choi, S. (2007). Kinematic Gait Analysis of the Hind Limb after Tibial Plateau Levelling Osteotomy and Cranial Tibial Wedge Osteotomy in Ten Dogs. *Journal of Veterinary Medicine Series A*, 54(10), 579-584.
- Leeson, T. S., Leeson, C. R. & Paparo, A. A. (1988). Specialized connective tissue: cartilage and bone. In M. Wonsiewicz & K. McCullough (Eds.), *Text/Atlas of Histology*. (2nd ed.). (pp. 159-194). W.B. Saunders, Philadelphia.
- Leighton, R. L. (1999). Preferred method of repair of cranial cruciate ligament rupture in dogs - A survey of ACVS diplomates specializing in canine orthopaedics. *Vet Surg*, 28,194

- Lewis, B., Allen, D., Henrikson, T. & Lehenbauer, T. (2008). Computed tomographic evaluation of the canine intercondylar notch in normal and cruciate deficient stifles. *Vet Comp Orthop Traumatol*, 21(2), 119-124.
- Lineberger, J. A., Allen, D. A., Wilson, E. R., Tobias, T. A., Shaiken, L. G., Shiroma J. T, Biller, D. S. & Lehenbauer, T. W. (2005). Comparison of radiographic arthritic changes associated with two variations of tibial plateau levelling. *Vet Comp Orthop Traumatol*, 18, 13-17.
- Lipowitz, A. J. (1993). Degenerative joint disease. In D. Slatter (Ed.), *Textbook of Small Animal Surgery*, (2nd ed.). (pp. 1921-1027). WB Saunders, Philadelphia.
- Luther, J. K., Cook, C. R. & Cook, J. L. (2009). Meniscal release in cruciate ligament intact stifles causes lameness and medial compartment cartilage pathology in dogs 12 weeks postoperatively. *Veterinary Surgery*, 38(4), 520-529.
- Mahn, M. M., Cook, J. L., Cook, C. R. & Balke, M. T. (2005). Arthroscopic verification of ultrasonographic diagnosis of meniscal pathology in dogs. *Vet Surg*, 34, 318-323.
- Mangram, A. J., Horan, T. C., Pearson, M. L., Silver, L. C. & Jarvis, W. R. (1999). Guideline for prevention of surgical site infection. *American Journal of Infection Control*, 27(2), 97-134.
- Manley, P. A. (2010). Intra-articular Stabilization. In P. Muir (Ed.) *Advances in the canine cranial cruciate ligament* (1st ed.). (pp. 189-193). Wiley-Blackwell.
- Maquet, P. (1976). Tibial tuberosity advancement. *Clin Orthop Rel Res*, 115, 225-230.
- Marshall, W., Hazewinkel, H., Mullen, D., De Meyer, G., Baert, K. & Carmichael, S. (2010). The effect of weight loss on lameness in obese dogs with osteoarthritis. *Veterinary Research Communications*, 34(3), 241-253.
- Marsolais, G.S., Dvorak, G., Conzemius, M.G. (2002). Effects of postoperative rehabilitation on limb function after cranial cruciate ligament repair in dogs. *Journal of the American Veterinary Medical Association*, 220(9), 1325-1330.
- Martins, T. L., Kahvegian, M. A. P., Leon-Roman, M. A., Otsuki, D. A., Fantoni, D. T. & Noel-Morgan, J. (2010). Comparison of the effects of tramadol, codeine, and ketoprofen alone or in combination on postoperative pain and on concentrations of blood glucose, serum cortisol, and serum interleukin-6 in dogs undergoing maxillectomy or mandibulectomy. *American Journal of Veterinary Research*, 71(9), 1019-1026.
- Mastrocinque, S. & Fantoni, D. T. (2003). A comparison of preoperative tramadol and morphine for the control of early postoperative pain in canine ovariohysterectomy. *Veterinary anaesthesia and analgesia*, 30(4), 220-228.
- Metelman, L. A., Schwarz, M., Salman, M. & Alvis, M. R. (1995). An evaluation of three different cranial cruciate ligament surgical stabilization procedures as they relate to postoperative meniscal injuries. A retrospective study of 665 stifles. *Veterinary and Comparative Orthopaedics and Traumatology*, 8, 118-23.
- Miller, W. H., Griffin, C. E. & Campbell, K. L. (2000). Dermatologica Therapy, in W. H. Miller, C. E. Griffin & K. L. Campbell (Eds.), *Muller and Kirk's Small Animal Dermatology* (6th ed.). (pp.207-273). Wiley-Blackwell.
- Millis, D. L., Durant, A., Headrick, J. & Weigel, J. P. (2008). Long term kinetic and kinematic comparison of cruciate-deficient dogs treated with tibial plateau levelling osteotomy or modified retinacular imbrications technique. *Proceedings of the Veterinary Orthopedic Society Annual Conference*. Big Sky, MT, 2008 , p. 12 .

- Miyatsu, M., Atsuta, Y., Watakabe, M. (1993). The physiology of mechanoreceptors in the anterior cruciate ligament. An experimental study in decerebrate-spinalised animals. *J Bone J Surg (Br)*, 75, 653-657.
- Mlacnik, E., Bockstahler, B. A., Muller, M., Tetrick, M. A., Nap, R. C. & Zentek, J. (2006). Effects of caloric restriction and a moderate or intense physiotherapy program for treatment of lameness in overweight dogs with osteoarthritis. *Journal of the American Veterinary Medical Association*, 229(11), 1756-1760.
- Monk, M., Preston, C. & McGowan, C. (2006). Effects of early intensive postoperative physiotherapy on limb function after tibial plateau levelling osteotomy in dogs with deficiency of the cranial cruciate ligament. *American Journal of Veterinary Research*, 67(3), 529-536.
- Montavon, P. M., Damur, D. M. & Tepic, S. (2002). Advancement of the tibial tuberosity for the treatment of cranial cruciate deficient canine stifle. Proceedings of the 1st World Orthopaedic Veterinary Congress. Munich, Germany, 152.
- Moore, K. W. & Read, R. A. (1996). Rupture of the cranial cruciate ligament in dogs - Part I. Compendium on Continuing Education for the Practicing Veterinarian, 18(3), 223-233.
- Morgan, J. P., Voss, K., Damur, D. M., Guerrero, T., Haessig, M & Montavon, P. M. (2010). Correlation of radiographic changes after tibial tuberosity advancement in dogs with cranial cruciate-deficient stifles with functional outcome. *Veterinary Surgery*, 39, 425-432.
- Morris, E. & Lipowitz, A. J. (2001). Comparison of tibial plateau angles in dogs with and without cranial cruciate ligament injuries. *J Am Vet Med Assoc*, 218(3), 363-366.
- Moucha, C. S., Clyburn, T. & Evans, R. P. (2011). Modifiable risk factors for surgical site infection. *Journal of Bone and Joint Surgery*, 93(4), 398-404.
- Muir, P. (2010). History and Clinical Signs of Cruciate Ligament Rupture. In P. Muir (Ed.), *Advances in the canine cranial cruciate ligament*, (1st ed.). (pp. 101-104). Wiley-Blackwell.
- Muzzi, L. A. L., Muzzi, R. A. L., Rezende, C. M. F. & Rocha, A. P. (2001). Ultra-sonografia da articulação fêmoro-tíbio-patelar em cães normais. *Ciência Animal*, 11, 209.
- Nazarali, A. (2013). Peri-operative use of antibiotics in tibial plateau leveling osteotomy surgeries performed on dogs and its effect on surgical site infections: 224 cases (2008-2010). In *Proceedings of the ACVS Symposium*, San Antonio, October 23-26.
- Nelson, S. A., Krotscheck, U., Rawlinson, J., Todhunter, R. J., Zhang, Z. & Mohammed, H. (2013). Long-term functional outcome of tibial plateau levelling osteotomy versus extracapsular repair in a heterogeneous population of dogs. *Veterinary Surgery*, 42(1), 38-50.
- Nicholson, M., Beal, M. & Shofer, F. (2002). Epidemiologic evaluation of postoperative wound infection in clean-contaminated wounds: a retrospective study of 239 dogs and cats. *Veterinary Surgery*, 31(6), 577-581.
- Nikolaou, V., Chronopoulos, E., Savvidou, C., Plessas, S., Giannoudis, P., Efstathopoulos, N. & Papachristou, G. (2008). MRI efficacy in diagnosing internal lesions of the knee: a retrospective analysis. *J Trauma Manage Outcomes*, 2(1), 4.
- Nisell, R., Németh, G. & Ohlsén, H. (1986). Joint forces in the extension of the knee: Analysis of a mechanical model. *Acta Orthop Scand*, 57, 41-46.
- Noorani, A., Rabey, N., Walsh, S. R. & Davies, R. J. (2010) Systematic review and meta-analysis of preoperative antisepsis with chlorhexidine versus povidone-iodine in clean-contaminated surgery. *Bone and Joint Surgery*, 97, 1614-1620.

- O'Connor, B. L. & Woodbury, P. (1991). The primary articular nerves to the dog's knee. *J Anat*, 134, 563-572.
- O'Donoghue, D. H., Rockwood, C. A. Jr., Frank, G. R., Jack, S. C. & Kenyon, R. (1966). Repair of the anterior cruciate ligament in dogs. *J Bone Joint Surg Am*, 48(3), 503-519.
- Ochi, H., Hara, Y., Asou, Y., Harada, Nezu, Y., Yogo, T., Shinomiya, K. & Tagawa, M. (2011) Effects of long-term administration of carprofen on healing of a tibial osteotomy in dogs. *Am J Vet Res*, 72(5), 634-41.
- Oei, E. H., Ginai, A. Z. & Hinink, M. G. (2007). MRI for traumatic knee injury: a review. *Seminars in Ultrasound, CT, and MR*, 28, 141-157.
- Oxley, B., Gemmill, T. J. & Renwick, A. R. (2013). Comparison of complication rates and clinical outcome between tibial plateau levelling osteotomy and a modified cranial closing wedge osteotomy for treatment of cranial cruciate ligament disease in dogs. *Veterinary Surgery*, 42(6), 739-750.
- Paatsama, S. (1952). Ligament injuries of the canine stifle joint: A clinical and experimental study. Thesis Helsinki.
- Paatsama, S. (1988). Long-Standing and Traumatic Ligament Injuries and Meniscal Ruptures of the Canine Stifle. *Veterinary Radiology*, 29(2), 54-56.
- Pacchiana, P. D., Morris, E., Gillings, S. L., Jessen, C. R. & Lipowitz, A. J. (2003). Surgical and postoperative complications associated with tibial plateau leveling osteotomy in dogs with cranial cruciate ligament rupture: 397 cases (1998–2001). *J Am Vet Med Assoc*, 222, 184-193.
- Patel, R. (2005). Biofilms and Antimicrobial Resistance. *Clinical Orthopaedics and Related Research*, & NA, 437, 41-47.
- Piermattei, D. L., Flo, G. L. & DeCamp, C. E. (2006). Rupture of cranial cruciate ligament. In D. L. Piermattei G. L. Flo & C. E. DeCamp (Eds.) *Brinker, Piermattei, and Flo's Handbook of Small Animal Orthopedics and Fracture Repair*, (4th ed.). (pp. 582-585). Saunders Elsevier, Missouri.
- Piermattei, D. L., Flo, G. L. & DeCamp, C. E. (2006). The stifle joint. In D. L. Piermattei, G. L. Flo & C. E. DeCamp (Eds.) *Brinker, Piermattei, and Flo's Handbook of Small Animal Orthopedics and Fracture Repair*, (4th ed.). (pp. 562-632). Saunders, Philadelphia.
- Plesman, R., Gilbert, P., Campbell, J. (2013). Detection of meniscal tears by arthroscopy and arthrotomy in dogs with cranial cruciate ligament rupture: a retrospective, cohort study. *Veterinary and Comparative Orthopaedics and Traumatology*, 26(1), 42-46.
- Pond, M. J. & Campbell, J. R. (1972). The canine stifle joint. I. Rupture of the anterior cruciate ligament. An assessment of conservative and surgical treatment. *J Small Anim Pract*, 13, 1-10.
- Powers, M. Y., Martinez, S. A., Lincoln, J. D., Temple, C. J. & Arnaiz, A. (2005). Prevalence of cranial cruciate ligament rupture in a population of dogs with lameness previously attributed to hip dysplasia: 369 cases (1994 – 2003). *J Am Vet Med Assoc*, 227, 1109-1111.
- Pozzi, A. & Kim, S. E. (2010). Biomechanics of the normal and cranial cruciate ligament-deficient stifle. In P. Muir (Ed.) *Advances in the canine cranial cruciate ligament* (1st ed.). (pp. 37-42). Wiley-Blackwell.
- Pozzi, A., Hildreth, B. E. 3rd. & Rajala-Schultz, P. J. (2008). Comparison of arthroscopy and arthrotomy for diagnosis of medial meniscal pathology: An ex vivo study. *Vet Surg*, 37, 749-755.

- Pozzi, A., Kowaleski, M. P., Apelt, D., Meadows, C., Andrews, C. M. & Johnson, K. A. (2006). Effect of medial meniscal release on tibial translation after tibial plateau levelling osteotomy. *Vet Surg*, 35, 486-494.
- Pozzi, A., Litsky, A., Field, J., Apelt, D. & Meadows, C., Johnson, K. (2008). Pressure distributions on the medial tibial plateau after medial meniscal surgery and tibial plateau levelling osteotomy in dogs. *Veterinary and Comparative Orthopaedics and Traumatology*, 21(1), 8-14.
- Priddy, N. H., Tomlinson, J. L., Dodam, J. R. & Hornbostel, J. E. (2003). Complications with and owner assessment of the outcome of tibial plateau leveling osteotomy for treatment of cranial cruciate ligament rupture in dogs: 193 cases (1997 – 2001). *J Am Vet Med Assoc*, 222, 1726-1732.
- Ragetly, C. A., Griffon, D. J., Mostafa, A. A., Thomas, J. E. & Hsiao-Wecksler, E. T. (2010). Inverse dynamics analysis of the pelvic limbs in Labrador Retrievers with and without cranial cruciate ligament disease. *Vet Surg*, 39(4), 513-522.
- Ralphs, S. C. & Whitney, W. O. (2002). Arthroscopic evaluation of menisci in dogs with cranial cruciate ligament injuries: 100 cases (1999 – 2000). *J Am Vet Med Assoc*, 221, 1601-1604.
- Reed, A. L., Payne, J. T. & Constantinescu, G. M. (1995). Ultrasonography anatomy of the normal canine stifle. *Vet Radiol Ultrasound*, 36, 315-321.
- Reif, U., DeJardin, L. M., Probst, C. W., DeCamp, C. E., Flo, G. L. & Johnson, A. L. (2004). Influence of limb positioning and measurement method on the magnitude of the tibial plateau angle. *Vet Surg*, 33, 368-375.
- Reif, U., Hulse, D. A. & Hauptman, J. G. (2002). Effect of tibial plateau levelling on stability of the canine cranial cruciate-deficient stifle joint: an in vitro study. *Vet Surg*, 31(2), 147-154.
- Reinke, J. D. (1982). Cruciate ligament avulsion injury in the dog. *J Am Anim Hosp Assoc*, 18, 257-264.
- Ritzo, M., Ritzo, B., Siddens, A., Summerlott, S. & Cook, J. (2014). Incidence and Type of Meniscal Injury and Associated Long-Term Clinical Outcomes in Dogs Treated Surgically for Cranial Cruciate Ligament Disease. *Veterinary Surgery*, 43(8), 952-958.
- Robins, G. M. (1990). The canine stifle joint. In W. G. Whittick (Ed.) *Canine Orthopedics*, (2nd ed.). (pp. 707-724). Lea & Febiger, Philadelphia, PA.
- Samii, V. F., Dyce, J., Pozzi, A., Drost, W. T., Mattoon, J. S., Green, E. M., Kowaleski, M. P. & Lehman, A. M. (2009). Computed tomographic arthrography of the stifle for detection of cranial and caudal cruciate ligament and meniscal tears in dogs. *Vet Radiol Ultrasound*, 50, 144-150.
- Sartor, A., Selmic, L. E., Withrow, S. J. & Ryan, S. D. (2013) Retrospective case series evaluating the incidence and risk factors affecting development of osteosarcoma following consecutive tibial plateau levelling osteotomies performed at a single institution between 1999-2009 (abstract 6). In The 40th Annual Conference of the Veterinary Orthopedic Society Park City, UT.
- Scavelli, T. D., Schrader S. C., Matthiesen, D. R. & Skorup, D. E. (1990). Partial rupture of the cranial cruciate ligament in the stifle in dogs (1982-1988). *J Am Vet Med Assoc*, 196, 1135-1138.
- Selmic, L. E., Ryan, S. D., Boston, S., Liptak, J. M., Culp, W. T., N., Sartor, A. J., Prpich, C. Y. & Withrow, S. J. (2014). Proximal tibial osteosarcoma following tibial plateau levelling

- osteotomy in 29 dogs: a Veterinary Society of Surgical Oncology Retrospective Case Series (1997-2011). *J Am Vet Med Assoc*, 244, 1053-1059.
- Showalter, B. M., Crantford, J. C., Russel, G. B., Marks, M. W., DeFranzo, A. J., Thompson, J. T., Pestana, I. A & David, L. R. (2014). The effect of reusable versus disposable draping material on infection rates in implant-based breast reconstruction: a prospective randomized trial. *Ann Plast Surg*, 72(6), 165-169.
- Siemering, G. H. (1978). Arthroscopy of dogs. *J Am Vet Med Assoc*, 172, 575-575.
- Singleton, W. B. (1957). The diagnosis and surgical treatment of some abnormal stifle conditions in the dog. *Vet Rec*, 69, 1387-1394.
- Slocum, B. & Devine, T. (1983). Cranial tibial thrust: A primary force in the canine stifle. *J Am Vet Med Assoc*, 183, 456-459.
- Slocum, B. & Devine, T. (1984). Cranial Tibial Wedge Osteotomy: A Technique for Eliminating Cranial Tibial Thrust in Cranial Cruciate Ligament Repair, *Journal of the American Veterinary Medical Association*, 184, 564-569.
- Slocum, B. & Slocum, T. D. (1993). Tibial plateau leveling osteotomy for repair of cranial cruciate ligament rupture in the canine. *Vet Clin North Am Small Anim Pract*, 23, 777-795.
- Slocum, B. & Slocum, T. D. (1998). Tibial plateau levelling osteotomy for cranial cruciate ligament. In M. J. Bojrab (Ed.), *Current Techniques in Small Animal Surgery*, (4th ed.). (pp. 1209-1215). PA, Lea & Febiger, Philadelphia.
- Stauffer, K. D., Tuttle, T. A., Elkins, A. D., Wehrenberg, A. P. & Character, B. J. (2006). Complications associated with 696 tibial plateau leveling osteotomies (2001–2003). *J Am Anim Hosp Assoc*, 42, 44-50.
- Steinberg, E. J., Prata, R. G., Palazzini, K. & Brown, D. C. (2011). Tibial tuberosity advancement for treatment of CrCL injury: complications and owner satisfaction. *Journal of the American Animal Hospital Association*, 47(4), 250-257.
- Stephan, J. S., McLaughlin, R. M. & Griffith, G. (1998). Water content and glycosaminoglycan disaccharide concentration of the canine meniscus. *Am J Vet Res*, 59, 213-216.
- Stouffer, D. C., Butler, D. L. & Kim, H. (1983). Tension - torsion characteristics of the canine anterior cruciate ligament — Part I: Theoretical framework. *J Biomech Eng*, 105, 154-159.
- Straw, M. (2005) What's your diagnosis? Fracture/implant-associated osteosarcoma following TPLO procedures. *Journal of Small Animal Practice*, 46(9), 457-459.
- Strom, H. (1990). Partial rupture of the cranial cruciate ligament in dogs. *Journal of Small Animal Practice*, 31, 137-40.
- Tanner, J. & Parkinson, H. (2004). Double gloving to reduce surgical cross-infection. *Cochrane Database Syst Rev*, (3), CD003087.
- Tashman, S., Anderst, W., Kolowich, P., Havstad, S. & Arnoczky, S. (2004). Kinematics of the ACL-deficient canine knee during gait: Serial changes over two years. *Journal of Orthopaedic Research*, 22(5), 931-941.
- Taylor, J., Langenbach, A., Marcellin-Little, D. J. (2011). Risk factors for fibular fracture after TPLO. *Veterinary Surgery*, 40(6), 687-693.

- Taylor-Brown, F., Meeson, R., Brodbelt, D., Church, D., McGreevy, P., Thomson, P. & O'Neill, D. (2015). Epidemiology of Cranial Cruciate Ligament Disease Diagnosis in Dogs Attending Primary-Care Veterinary Practices in England. *Veterinary Surgery*, 44(6), 777-783.
- Tepic, S., Damur, D. & Montavon, P. M. (2002). Biomechanics of the stifle joint. Proceedings of the 1st World Orthopaedic Veterinary Congress (pp. 189-190). Munich, Germany.
- Thieman, K. M., Pozzi, A., Ling, H. Y., Lewis, D. D. & Horodyski, M. (2009). Contact mechanics of simulated meniscal tears in cadaveric canine stifles. *Vet Surg*, 38, 803-810.
- Thieman, K., Pozzi, A., Ling, H. and Lewis, D. (2010). Comparison of Contact Mechanics of Three Meniscal Repair Techniques and Partial Meniscectomy in Cadaveric Dog Stifles. *Veterinary Surgery*, 39(3), 355-362.
- Thieman, K., Tomlinson, J., Fox, D., Cook, C. & Cook, J. (2006). Effect of Meniscal Release on Rate of Subsequent Meniscal Tears and Owner-Assessed Outcome in Dogs with Cruciate Disease Treated with Tibial Plateau Levelling Osteotomy. *Vet Surgery*, 35(8), 705-710.
- Tirgari, M. (1978). The surgical significance of the blood supply of the canine stifle joint. *J Small Anim Pract*, 19, 451-462.
- Tivers, M. S., Commerford, E. J. & Owen, M. R. (2009). Does a fabella-tibial suture alter the outcome for dogs with cranial cruciate ligament insufficiency undergoing arthrotomy and caudal pole medial meniscectomy?. *Vet Comp Orthop Traumatol*, 22, 283-288.
- Tivers, M. S., Mahoney, P. & Corr, S. (2008). A. Canine stifle positive contrast computed tomography arthrography for assessment of caudal horn meniscal injury: A cadaver study. *Vet Surg*, 37, 269-277.
- Tivers, M., Mahoney, P., Baines, E. & Corr, S. (2009). Diagnostic accuracy of positive contrast computed tomography arthrography for the detection of injuries to the medial meniscus in dogs with naturally occurring cranial cruciate ligament insufficiency. *Journal of Small Animal Practice*, 50(7), 324-332.
- Trampuz, A. & Zimmerli, W. (2006). Diagnosis and treatment of infections associated with fracture-fixation devices. *Injury*, 37(2), S59-S66.
- Tuttle, T. A. & Manley, P. A. (2009). Risk factors associated with fibular fracture after tibial plateau leveling osteotomy. *Vet Surg*, 38(3), 355-360.
- Vasseur, P. B. & Arnoczky, S. P. (1981). Collateral ligaments of the canine stifle joint: anatomic and functional analysis. *Am J Vet Res*, 42(7), 1133-1137.
- Vasseur, P. B. & Berry, C. R. (1992). Progression of stifle osteoarthritis following reconstruction of the cranial cruciate ligament in 21 dogs. *J Am Anim Hosp Assoc*, 28, 129-136.
- Vasseur, P. B. (1984). Clinical results following nonoperative management for rupture of the cranial cruciate ligament in dogs. *Vet Surg*, 13(4), 243-246.
- Vasseur, P. B. (2003) Stifle joint. In D. Slatter (Ed.), *Textbook of Small Animal Surgery*, (3rd ed.). (pp. 2090-133). WB Saunders, Philadelphia.
- Vasseur, P. B., Johnson, A. L., Budsberg, S. C., Lincoln, J. P., Whitehair, J. G & Lentz, E. L. (1995). Randomized, controlled trial of the efficacy of carprofen, a nonsteroidal antiinflammatory drug, in the treatment of osteoarthritis in dogs. *J Am Vet Med Assoc*, 206, 807-811.
- Vasseur, P. B., Levy, J., Dowd, E. & Eliot, J. (1988) Surgical wound infection rates in dogs and cats. *Veterinary Surgery*, 17(2), 60-64.

- Vasseur, P. B., Pool, R. R., Arnoczky, S. P. & Lau, R. E. (1985). Correlative biomechanical and histologic study of the cranial cruciate ligament in dogs. *Am J Vet Res*, 46, 1842-1854.
- Vianna, M. & Roe, S. (2006). Mechanical Comparison of Two Knots and Two Crimp Systems for Securing Nylon Line Used for Extra-Articular Stabilization of the Canine Stifle. *Vet Surgery*, 35(6), 567-572.
- Wagner, A., Walton, J., Hellyer, P., Gaynor, J. & Mama, K. (2002). Use of low doses of ketamine administered by constant rate infusion as an adjunct for postoperative analgesia in dogs. *Journal of the American Veterinary Medical Association*, 221(1), 72-75.
- Ward, W. G. Sr., Cooper, J. M., Lippert, D., Kablawi, R. O., Neiberg, R. H. & Sherertz, R. J. (2014). Glove and gown effects on intraoperative bacterial contamination. *Ann Surg*, 259(3), 591-597
- Warzee, C. C., Dejardin, L. M., Arnoczky, S. P. & Perry, R. (2001). Effect of tibial plateau levelling on cranial and caudal tibial thrusts in canine cranial cruciate-deficient stifles: An in vitro experimental study. *Vet Surg*, 30, 278-286.
- Watt, P. R., Sommerlad, S. M. & Robins, G. M. (2000). Tibial wedge osteotomy for treatment of cranial cruciate rupture. Proceedings 10th Annual American College of Veterinary Surgeons Symposium, September 21–24, 478.
- Whitehair, J. G., Vasseur, P. B. & Willits, N. H. (1993). Epidemiology of cranial cruciate ligament rupture in dogs. *J Am Vet Med Assoc*, 203, 1016-1019.
- Whitney, W. O. (2003). Arthroscopically assisted surgery of the stifle joint. In B. S. Beale, D. A. Hulse, K. S. Schulz & W. O. Whitney (Eds.), *Small Animal Arthroscopy* (1st ed.). (pp. 117-157). WB Saunders, Philadelphia.
- Wilke, V. L., Conzemius, M. G., Kinghorn, B. P., Macrossan, P. E., Cai, W. & Rothschild, M. F. (2006). Inheritance of rupture of the cranial cruciate ligament in Newfoundlands. *J Am Vet Med Assoc*, 228, 61-64.
- Wilke, V., Robinson, D., Evans, R., Rothschild, M. & Conzemius, M. (2005). Estimate of the annual economic impact of treatment of cranial cruciate ligament injury in dogs in the United States. *Journal of the American Veterinary Medical Association*, 227(10), 1604-1607.
- Williams, J., Tomlinson, J. & Constantinescu, G. M. (1994). Diagnosing and treating meniscal injuries in the dog. *Vet Med*, 89, 42-47.
- Windolf, M., Leitner, M., Schwieger, K., Pearce, S. G., Zeiter, S., Schneider, E. & Johnson, K. A. (2008). Accuracy of fragment positioning after TPLO and effect on biomechanical stability. *Vet Surg*, 37, 366-373.
- Wingfield, C., Amis, A. A., Stead, A. C. & Law, H. T. (2000). Cranial cruciate stability in the Rottweiler and racing Greyhound: An in vitro study. *J Small Anim Pract*, 41, 193-197.
- Witsberger, T. H., Villamil, J. A., Schultz, L. G., Hahn, A. W & Cook, J. L. (2008). Prevalence of and risk factors for hip dysplasia and cranial cruciate ligament deficiency in dogs. *J Am Vet Med Assoc*, 232, 1818-1824.
- Wolf, R. E., Scavelli, T. D., Hoelzler, M. G., Fulcher, R. P. & Bastian, R. P. (2012). Surgical and postoperative complications associated with tibial tuberosity advancement for cranial cruciate ligament rupture in dogs: 458 cases (2007-2009). *Journal of the American Veterinary Medical Association*, 240(12), 1481-1487.

- Yahia, L. H. & Douin, G. (1989). Microscopical investigation of canine anterior cruciate ligament and patellar tendon: Collagen fascicle morphology and architecture. *J Orthop Res*, 7, 243-251.
- Yahia, L. H., Newman, N. M. & St Georges, M. (1992). Innervation of the canine cruciate ligaments. A neurohistological study. *Anat Histol Embryol*, 21, 1-8.
- Yeadon, R., Fitzpatrick, N., Kowaleski, M. P. (2011). Tibial tuberosity transposition advancement for treatment of medial patellar luxation and concomitant cranial cruciate ligament disease in the dog. Surgical technique, radiographic and clinical outcomes. *Veterinary and Comparative Orthopaedics and Traumatology*, 24(1), 18-26.
- Yeap, J. S., Lim, J. W., Vergis, M., Au Yeung, P. S., Chiu, C. K. & Singh, H. (2006). Prophylactic antibiotics in orthopaedic surgery: guidelines and practice. *Med J Malaysia*, 61(2), 181-188.