


ANTROPOLOGIA
PORTUGUESA



VOLUME 32/33 * 2015/2016

CENTRO DE
INVESTIGAÇÃO
EM ANTROPOLOGIA
E SAÚDE
UNIVERSIDADE
DE COIMBRA

Osteological analysis of a skeleton with intentional dental modifications, exhumed from *Largo do Carmo* (17th–18th centuries), Lisbon



Análise osteológica de um esqueleto com modificações dentárias intencionais, exumado do Largo do Carmo (séculos XVII - XVIII), Lisboa

Rute V. Alves¹, Susana J. Garcia¹, António Marques², Sofia N. Wasterlain^{3*}

Abstract This paper presents the osteological analysis of a young adult exhumed from the cemetery associated to *Igreja do Carmo*, Lisbon, Portugal, during the second archaeological intervention in 2010/2011. Although the cemetery had been used between the beginning of the 15th century and 1755 AD, the archaeological context of the burial allows us to gauge its dating between the 17th and the 18th centuries.

Resumo Neste trabalho apresenta-se a análise osteobiográfica de um jovem adulto exumado do cemitério associado à Igreja do Carmo, Lisboa, durante a 2.^a campanha de intervenções arqueológicas decorrida em 2010/2011. Ainda que o cemitério tenha sido usado entre inícios do século XV e 1755 A.D., o contexto arqueológico da sepultura permite-nos balizar a sua datação entre os séculos XVII e XVIII.

¹ Instituto Superior de Ciências Sociais e Políticas, Centro de Administração e Políticas Públicas, Museu Nacional de História Natural e da Ciência, Universidade de Lisboa, Lisboa, Portugal.

² Centro de Arqueologia de Lisboa, Departamento de Património Cultural Câmara Municipal de Lisboa, Lisboa, Portugal.

³ Centro de Investigação em Antropologia e Saúde, Departamento de Ciências da Vida, Universidade de Coimbra, Coimbra, Portugal.

* Corresponding author: sofiawas@antrop.uc.pt

The skeleton is distinguished by a cranial morphology suggestive of an African origin and intentional dental modifications. These consist of the removal of both incisal angles of the upper incisors, which corresponds to a practice related to culture, commonly made in sub-Saharan Africa since prehistoric times. A periapical lesion was associated to the maxillary right central incisor that was apparently healthy but modified. The left clavicle showed bone remodelling along the shaft. Five ribs displayed new bone deposition, and the sternal end of the first left rib was deformed and destroyed. The differential diagnosis of the lesions gave rise to several possible pathological conditions, namely, treponematoses and chronic respiratory disease, particularly tuberculosis. Various macroscopic aspects and the geographical context lead us to consider venereal syphilis as the most probable diagnosis. Considering that, during the 16th century, Lisbon had become a fundamental part of the intercontinental maritime routes, it is not surprising that African people were buried in the cemeteries of Lisbon, allowing us to learn more about their lives and deaths.

Keywords: Cultural body modifications; venereal syphilis; Modern Age; Africans; Portugal.

O esqueleto destaca-se pela morfologia craniana sugestiva de uma origem africana e pelas modificações dentárias intencionais. Estas consistem na remoção de ambos os ângulos incisais dos incisivos superiores, o que corresponde a uma prática cultural, comumente efetuada na África subsariana desde tempos pré-históricos. De destacar uma lesão periapical associada ao incisivo central superior direito, que se encontra hígido mas modificado. A diáfise da clavícula esquerda exibe reação óssea remodelada do perióstio, cinco costelas apresentam formação óssea incorporada no perióstio ao longo do colo e a articulação esternal da primeira costela esquerda encontra-se deformada. Várias condições patológicas foram consideradas aquando do diagnóstico diferencial destas lesões, nomeadamente as treponematoses e a doença respiratória crónica, particularmente a tuberculose. As características macroscópicas das lesões e o contexto geográfico dos achados favorecem o diagnóstico de sífilis venérea. Considerando que, durante o século XVI, Lisboa se tornou num eixo fundamental das rotas marítimas intercontinentais, não é de estranhar que pessoas africanas tenham sido sepultadas nos cemitérios de Lisboa, permitindo-nos reconstruir as suas vidas e mortes.

Palavras-chave: Modificações corporais culturais; sífilis venérea; Idade Moderna; africanos; Portugal.

Case Report

The practice of intentional dental modifications is well-documented among pre-historical and historical African populations (e.g. Almeida, 1953; Santos, 1962; Dias and Dias, 1964; Pindborg, 1969; Redinha, 1974; Inoue et al., 1995; Finucane et al., 2008; Reichart et al., 2008). In Africa, individuals from different regions and/or ethnic groups have modified teeth through filing, ablation, staining, and drilling with inlays (Barnes, 2010). It is considered a cultural practice related to rites of passage, group identity, mourning, or aesthetic reasons (Milner and Larsen, 1991; Finucane et al., 2008; Barnes, 2010). It is usually performed in the anterior teeth, which correspond to the most visible ones, sometimes to a specific sex. Besides, depending on the reasons, there may be age specificity regarding the time at which it is done (Jones, 1992). Although the intention behind dental modifications is difficult to identify from archaeological evidence alone, their pattern and location vary geographically and with ethnicity (Mower, 1999; Finucane et al., 2008), which can give clues into the individuals who present them. Recently, Wasterlain et al. (2015) performed a study on intentional dental modifications in a large sample of enslaved individuals from the 15th–17th centuries,

recovered from *Valle da Gafaria*, Lagos (Portugal). This was the first time that intentional dental modifications were reported for the Portuguese territory in the osteoarchaeological literature, being extremely important for a better understanding of dental practices among African people from the 15th–17th centuries, and more specifically in enslaved groups.

In 2010/2011, one incomplete skeleton exhibiting several distinguishable characteristics, namely a distinctive cranial morphology as well as intentional dental modifications, was recovered from a cemetery located outside the Igreja do Carmo, Lisbon (Portugal) (Figure 1). Taking into consideration the unusual nature of the features found in this individual as well as the scarcity of reports in the osteoarchaeological literature, it is considered important to analyse and describe this case in more detail. Moreover, the individual under analysis presents several pathological lesions in the postcranial skeleton, for which we try to make the differential diagnosis.

Archaeological background

In 2010/2011, previously to the implementation of the urban renewal project of the surroundings of the Church and Convent of Carmo in Lisbon, a team from Lisbon City Council's



Figure 1. (a) Location of Lisbon in Portugal; (b) Location of the *Igreja do Carmo* in Lisbon; (c) Aerial view of the Church and Convent of Carmo.

Centro de Arqueologia de Lisboa ('Lisbon Archaeological Centre') undertook the archaeological excavations. During these works, 42 individual interments were found, including adults ($n=21$) and sub-adults ($n=20$). In one case, the osteological remains were not sufficiently preserved

to know if it was an adult or a sub-adult. From the 21 adults, eight were females and four were males. In nine adult individuals it was not possible to determine sex. Most of the inhumations showed a West/East orientation, like the religious temple, and were buried on the field surrounding its

South and West fronts, which in the 17th century began to be partially urbanised.

The Church and Convent of Carmo were initially built after the Portuguese victory in the Aljubarrota Battle in 1385 AD, against Castile/Spain, led by Nuno Álvares Pereira, one of the most important and powerful noblemen at the time (Santa Ana, 1745; Pereira, 1989). Due to the soils instability, the construction of this Gothic monument was only achieved at the third attempt, since the structure collapsed during the first two attempts (Sequeira, 1939). It was repaired after the 1531's earthquake, and during the 17th century its urban context was deeply transformed, with the sacrifice of part of the pre-existent cemetery (Marques and Bastos, 2013). Following the 1755 earthquake, it only had some small incomplete repairs, and it was decided by the authorities to leave it as a ruin and a memory of that tragic event.

Despite the graveyard location in an urban area, at that time it was not a public cemetery, only receiving individuals who were either economic patrons or members of some religious brotherhood related to this church (there are almost 40 known brotherhoods for this church, among which the brotherhood of "Jesus Mary Joseph of the Black men", documented since 1571 AD). Therefore, we can suppose that most of these individuals buried outside the church belonged mainly to a middle social level. In fact, along the Southern façade there

are some inscriptions referring to some professions, like shoemaker or tailor (Lahon, 1999).

After 1755 AD, the southern front of the graveyard was rebuilt and the construction of its new foundations caused its partial removal, exposing human remains, among which those from the individual under analysis. Such archaeological context allows us to gauge its dating between the 17th and the 18th centuries.

Material and methods

The skeleton (individual E10 recovered from area 1 survey 1, Figure 2) is



Figure 2. Field photo of the burial of the individual E10 recovered from *Igreja do Carmo* (Lisbon, Portugal).

represented by the skull, upper chestwall, shoulder girdle, proximal end of the right humerus, and a fragment of the right radius. All teeth were present and fully erupted with the exception of the left upper third molar and the left lower central incisor which were lost postmortem.

The individual ancestry was assessed through non-metrical traits, more specifically the cranial morphological traits recommended by Rhine (1990), and through the metrical method programme *AncesTrees* developed by Navega and colleagues (2015).

The age-at-death estimate was made from the epiphyseal fusion of the bones (Ferembach et al., 1980) and the sequence of formation and eruption of teeth (Ubelaker, 1989; Cardoso et al., 2010). The sexual diagnosis of the individual was hampered by the fact that the hip bones were not recovered. The existing methodologies to estimate sex on the basis of other cranial and postcranial bones are not considered as reliable for individuals of African ancestry. Despite that, sex estimation of the present individual was tried through the discriminant function equations developed by Dayal and colleagues (2008) using the skull of black South Africans.

Enamel defects (hypoplasia or others) and oral pathologies were investigated as suggested by Hillson (2001). Periapical

inflammation and dental wear were recorded according to Dias and Tayles (1997) and Smith (1984), respectively. Intentional dental modifications were categorized according to the number of removed incisal angles, their position, tooth type and affected jaw, following Almeida (1953, 1957) modified by Wasterlain and colleagues (2015).

The pathological lesions observed in the bones were scrutinized according to Ortner (2008).

Results

Individual's biological profile

The sternal epiphyses of the clavicles were still in fusion. The vertebral rings were already fused and the third molars' roots were completely formed. All these data allowed us to infer that we are in the presence of an individual most probably on its early twenties.

The application of the equations developed by Dayal and collaborators (2008) suggested a female individual (average accuracy 85.0%). The cranial morphological traits presented by this individual — namely a wide nasal opening, a small nasal spine, a nasal opening flared, a rectangular orbital shape, a hyperbolic dental arcade, vertical zygomatics, large prognathism,

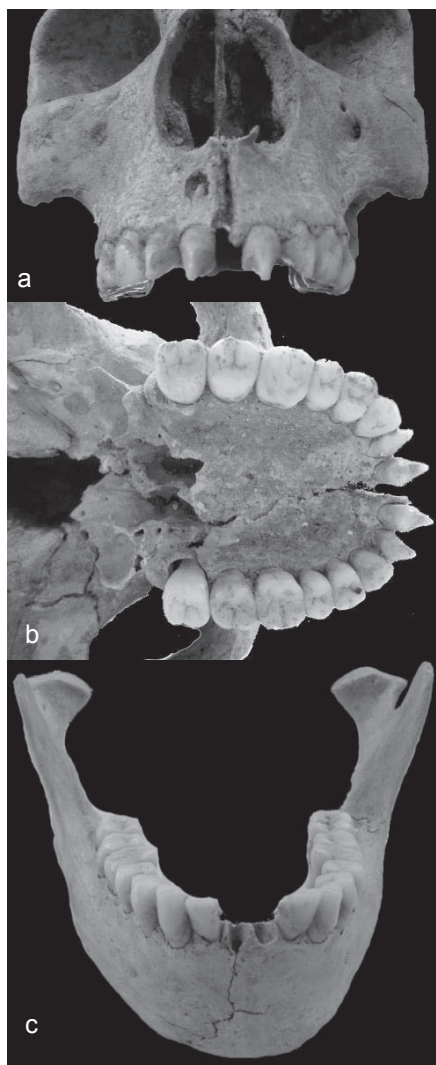


Figure 3. a) Frontal view of the skull and upper dentition. Note the periapical lesion in the buccal plate of the alveolar process at the apex of the root of the right upper central incisor; b) inferior view of the skull and upper dentition. Both central and lateral incisors are intentionally modified, resulting in pointed teeth; c) Anterior view of the mandible and lower dentition, which is not modified.

and an S-shaped zygomaticomaxillary suture — are consistent with an African ancestry. Moreover, the upper anterior teeth exhibited dental modifications (Figure 3), which is also compatible with the African ancestry estimation.

The ancestry was also assessed based on metric analysis, running the *AncesTrees* programme developed by Navega and colleagues (2015) with 13 cranial measurements. The results of this test strongly suggest an individual from Sub-Saharan Africa (Membership=1; p-value=0.79; Accuracy=0.92; Positive Predictive Value=0.91).

Intentional dental modifications

All upper incisors presented removal of both mesial and distal incisal angles, being the alterations consistent with filing (Figure 3a, b). There were no evidences of drilling with inlays, staining or ablation. Neither the right lower central incisor (the left was lost postmortem) nor the lateral incisors were modified. Regarding the pattern of dental modification, this individual showed his/her upper teeth modified according to pattern no. 3 as described by Wasterlain and collaborators (2015).

Oral pathology and dental wear

Linear enamel hypoplasia was apparent on incisors and canines. Calculus was generalized on the lingual side of the teeth. Dental wear was slight to

moderate (mean dental wear = grade 3). A cavitated carious lesion was observed in the distal interproximal surface of the left lower first molar.

A hollow bony lesion 5.1 mm wide and 7.6 mm height was found in the buccal plate of the alveolar process at the apex of the root of the right upper central incisor (Figure 3a). There is no perforation into the lingual plate of the alveolar process. The interior bony walls of the opening are well demarcated, smooth and rounded. The corresponding tooth was apparently caries-free but intentionally modified.

Pathological alterations of the bones

Five ribs (four left and one right) show new bone deposits along their shaft. The sternal articular surface of the first left rib is noticeably deformed (Figure 4).

The diaphysis of the left clavicle displays bone remodelling, affecting around 2/3 of the surface but being

more pronounced at the sternal articular surface (Figure 5). Pathological fractures were not found. The right clavicle does not present any pathological alterations.

Discussion

The intentional dental modifications observed in the individual under study correspond to a practice related to culture and commonly made in sub-Saharan Africa since prehistoric times (Gould et al., 1984; Jones, 1992; Fabian and Mumghamba, 2007; Finucane et al., 2008). In fact, the cranial morphological and metric traits presented by this individual are consistent with an African ancestry. Considering that, during the 16th century, Lisbon had become a fundamental part of the intercontinental maritime routes, it is not surprising that people from elsewhere have been buried in the cemeteries of Lisbon. It

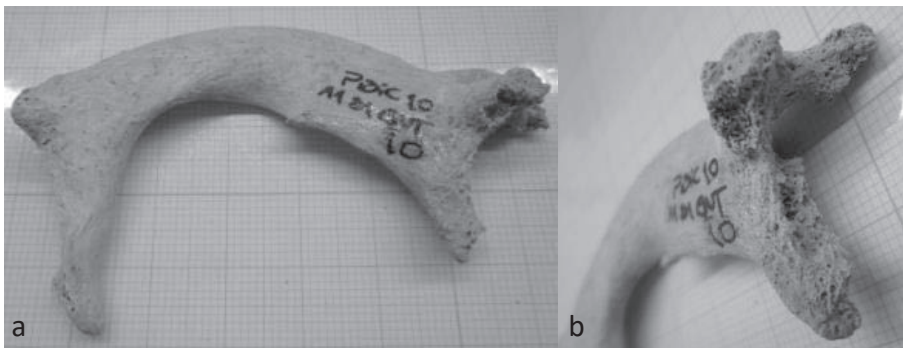


Figure 4. a) Upper view of the first left rib with great destruction of the sternal articular surface; b) Close up of the pathological alterations registered in the first left rib.

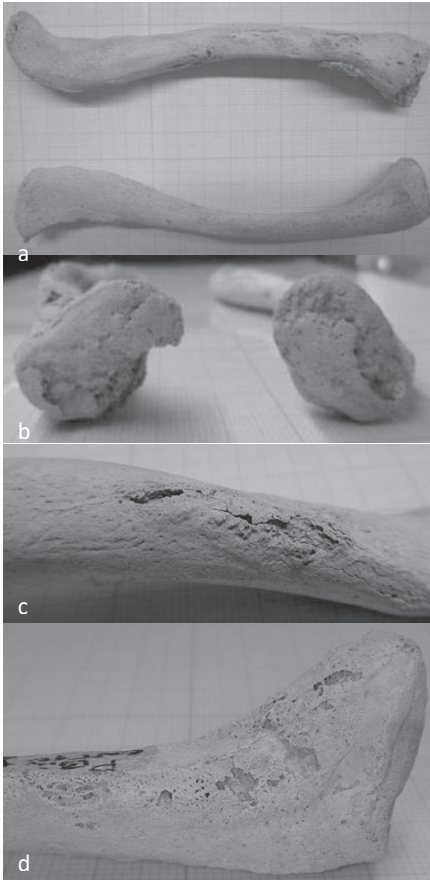


Figure 5. a) Superior view of the left clavicle (top) and inferior view of the right clavicle (bottom); b) Sternal articular surfaces of the clavicles. Notice that the fusion process was underway; c) Bone remodelling of the diaphysis of the left clavicle; d) Close up of the pathological alterations observed on the sternal end of the left clavicle.

should be recalled that the individual was inhumed in an urban non-parochial

cemetery used since the early 15th century (the construction of the religious complex had begun in 1389, during a period of about 20 years). Besides, it is thought that the individuals interred in this necropolis were mainly related to the different brotherhoods in the monastery and the church, and, from the 17th century onwards, also to the Third Order of Carmelites. In fact, according to the historical sources, in the 16th century there were already brotherhoods with Africans in the Convent of Carmo (e.g., *Irmandade de Jesus Maria José dos Homens Pretos*). There are also death settlements reporting the burial of ‘black individuals’ in this space (e.g., on May 7, 1593, *Maria Cabeceira “molher preta”* — Arquivo Nacional da Torre do Tombo, *Freguesia do Sacramento/Registos Mistos*, Cx. 2). After the earthquake of 1755, the necropolis was disabled. Unfortunately, it is not possible to infer a more specific geographic origin for this individual only based on the type and pattern of dental modifications because, as already highlighted by Wasterlain and collaborators (2015), several African ethnic groups modify their teeth in the same way. Nevertheless, the pattern of modification (number 3, following Wasterlain et al., 2015) is comparable to practices observed in sub-Saharan Africa. Pointed teeth as a result of filing of the anterior upper teeth were registered by Reichart and collaborators (2008) in skulls

from the early 20th century Cameroon. Also, several ethnic groups from Mali, Nigeria, the Central African Republic, the Democratic Republic of Congo, Angola, Mozambique, Zambia and Zimbabwe presented the same kind of alteration (Almeida, 1953; Santos, 1962; Dias and Dias, 1964; Gould et al., 1984; Jones, 1992; Fabian and Mumghamba, 2007; Finucane et al., 2008). In a skeletal sample of enslaved Africans found at Lagos, Portugal, Wasterlain and collaborators (2015) found seven individuals (two sub-adults and five adults) with a similar pattern of dental modification but were also unable to establish a specific geographic/ethnic origin for them. In order to refine the geographic provenance of the individual under analysis, ancient DNA studies and isotopic analyses should be performed in the future.

Intentional dental modifications may predispose teeth to oral pathology, namely periapical inflammation, through the direct exposure of the dental pulp and/or the traumatic injury resulting from the procedure's technique, which seems to be the case of this individual. The reported signs of the lesion at the apex of the root of the right upper central incisor (that was apparently caries-free but modified) suggest a chronic dental apical lesion, most probably a periapical granuloma or an apical periodontal cyst (Dias and Tayles, 1997; Dias et al., 2007). Such conditions are usually benign and

relatively asymptomatic. If present, the symptoms are confined to slight pain when biting on solid food. There are no systemic effects associated to granulomata or apical cysts (Dias and Tayles, 1997).

Linear enamel hypoplasia was registered on the incisors and canines of this individual. Such developmental defects are commonly referred as non-specific stress indicators because several conditions have been related to their origin, namely fever and starvation (Hillson and Bond, 1997).

The individual presents postcranial bone lesions consistent with infectious disease, although the differential diagnosis is difficult due to incomplete recovery of the skeleton.

The lesions observed in the clavicle and sternal end of the first rib have been reported in clinical cases of treponematoses, particularly venereal syphilis (Ortner, 2011a). The lesions registered in the body of the ribs may have been caused by the same condition or by a chronic respiratory disease. Similar lesions to those observed in the body of the ribs have been described by other researchers in the context of respiratory diseases, like tuberculosis (Matos and Santos, 2006). On the other hand, similar osteolytic changes of the first rib have been observed in cases of syphilis (McGladdery, 1950). The clavicular involvement is unusual in

systemic infectious diseases except syphilis (Ortner, 2008) and the bilateral involvement of the clavicles is unlikely associated with any other disorder (Ortner, 2011b), but in the present case the involvement of the clavicle is unilateral. The anterior thickening at the sternal end of the clavicle was also reported in several clinical cases of syphilis (Dorne and Zakon, 1935; Yang, 1940), even congenital (Erdal, 2006). In fact, the clavicle is, after the tibia, the long bone more frequently affected by this condition (Aufderheide and Rodríguez-Martín, 1998). The absence of pathognomonic lesions of syphilis (e.g., *caries sicca*) or other lesions frequently associated with this disease (e.g., alterations in the rhinomaxillary region) hinders the diagnosis and caution is therefore required. However, according to Ortner (2008), in treponemoses, one can have skull lesions without postcranial involvement and *vice versa*. In the present case, the tibiae were not recovered, and, from the forearm, only the shaft of the right radius was available to study. These areas are often affected by syphilis but are not considered pathognomonic lesions of the disease.

In case of confirmed treponemal disease, this is divided into four types: venereal syphilis, bejel, yaws and pinta, which are geographically restricted. Given that pinta is limited to the tropical regions of America (Aufderheide and Rodríguez-Martín, 1998), it was not

considered as possible diagnosis in the present case. Yaws affects especially populations with a low level of hygiene in tropical and subtropical humid areas whereas bejel is present in rural populations in temperate and subtropical non-humid regions (Aufderheide and Rodríguez-Martín, 1998). Venereal syphilis occurs primarily in urbanized populations in all geographic regions (Aufderheide and Rodríguez-Martín, 1998). From the remains under analysis, it is not possible to differentiate venereal syphilis from yaws or bejel. All conditions are caused by spirochetes of the genus *Treponema* and can affect the bone in similar forms (Waldron, 2009). However, it should be highlighted that syphilis was a common disease in Europe after the end of the 15th century (Quétel, 1990) and was present in Lisbon. Codinha (2002) described two individuals with *caries sicca* diagnosed as venereal syphilis, and Cardoso and Lopes (2000) reported an individual with extensive and symmetrical lesions in the femurs and tibiae. Both cases were exhumed from *Convento do Carmo*, the same origin of the currently described individual.

Conclusion

This article presents details on dental intentional modifications and skeletal

pathological changes in a young adult female from the 17th–18th centuries from Lisbon, Portugal. The dental modifications of the upper central incisors and the cranial morphology suggest a sub-Saharan African origin to the individual, which is supported by the historical context. Despite the impossibility to infer a more specific geographic origin or the motivation/function behind such cultural practice, the detailed study of the intentional dental modifications presented is extremely important for a better understanding of dental practices among African people who lived in Lisbon in the 17th–18th centuries, and it constitutes evidence of their acculturation into the Portuguese society of the time. Exuberant bone pathological lesions, both destructive and proliferative, were found in the clavicle and in five ribs. The lesions of the ribs are common in cases of respiratory diseases, like tuberculosis, but the involvement of the clavicle is more frequent in treponemal diseases. A definite diagnosis of treponemal disease is hindered by the absence of pathognomonic lesions in the tibiae or in the skull.

Further studies should be made, namely concerning ancient DNA studies and isotope analysis, not only to help refine a more exact geographic provenance of this individual but also to enlighten us further about sex, ancestry and pathology.

Acknowledgements

The authors would like to thank the excavation team, *Centro de Arqueologia de Lisboa*, and *Centro de Investigação em Antropologia e Saúde* (CIAS). This work was financed by national funds by FCT — *Fundação para a Ciência e Tecnologia*, under the project with the reference UID/ANT/00283/2013. The authors also acknowledge the anonymous reviewers whose valuable comments and suggestions allowed us to improve the manuscript.

References

- Almeida, R. 1953. Mutilações dentárias nos Negros da Lunda. *Anais do Instituto de Medicina Tropical*, 10: 3602– 3639.
- Almeida, R. 1957. *Subsídios para o estudo da Antropologia na Lunda. Mutilações dentárias nos negros da Lunda*. Lisboa, Companhia de Diamantes de Angola (Diamang), Publicações Culturais, n.º 33.
- Aufderheide, A. C.; Rodríguez-Martín, C. 1998. *The Cambridge encyclopedia of human paleopathology*. Cambridge, Cambridge University Press.
- Barnes, D. M. 2010. *Dental modification: an anthropological perspective*. [Online] University of Tennessee Honors Thesis Project. Consultado em 20-06-2015. Disponível em: <http://trace>.

tennessee.edu/cgi/viewcontent.cgi?article=2385&context=utk_chanhonoproj

- Cardoso, H.; Lopes, L. A. 2000. Possível caso de sífilis em fémur e tibia direitos de um indivíduo proveniente do carneiro da segunda capela da epístola do convento do Carmo de Lisboa (Sécs. XVI-XIX). In: Jorge, V. O. (ed.) *Contributos das ciências e das tecnologias para a arqueologia da Península Ibérica. Actas do 3.º Congresso de Arqueologia Peninsular*, UTAD, Vila Real, Setembro 1999. Porto, ADECAP: 459–463.
- Cardoso, H. F. V.; Heuzé, Y.; Júlio, P. 2010. Secular change in the timing of dental root maturation in Portuguese boys and girls. *American Journal of Human Biology*, 22(6): 791–800. DOI: 10.1002/ajhb.21084.
- Codinha, S. 2002. Two cases of venereal syphilis from the cemetery of the Igreja do Convento do Carmo (Lisboa). *Antropologia Portuguesa*, 19: 29–40.
- Dayal, M. R.; Spocter, M. A.; Bidmos, M. A. 2008. An assessment of sex using the skull of black South Africans by discriminant function analysis. *Homo — Journal of Comparative Human Biology*, 59(3): 209–221. DOI: 10.1016/j.jchb.2007.01.001.
- Dias, J.; Dias, M. 1964. *Os Macondes de Moçambique*. Lisboa, Junta de Investigações do Ultramar.
- Dias, G.; Tayles, N. 1997. 'Abscess cavity' — a misnomer. *International Journal of Osteoarchaeology*, 7(5): 548–554. DOI: 10.1002/(SICI)1099-1212(199709/10)7:5<548::AID-OA369>3.0.CO;2-I.
- Dias, G. J.; Prasad, K.; Santos, A. L. 2007. Pathogenesis of apical periodontal cysts: guidelines for diagnosis in palaeopathology. *International Journal of Osteoarchaeology*, 17(6): 619–626. DOI: 10.1002/oa.902.
- Dorne, M.; Zakon, S. J. 1935. Enlargement of one sternoclavicular articulation as a valuable clinical sign of late prenatal (congenital) syphilis. *Archives of Dermatology and Syphilology*, 32(4): 602–604. DOI: 10.1001/archderm.1935.01470040059011.
- Erdal, Y. S. 2006. A Pre-Columbian case of congenital syphilis from Anatolia (Nicaea, 13th Century AD). *International Journal of Osteoarchaeology*, 16(1): 16–33. DOI: 10.1002/oa.802.
- Fabian, F. M.; Mumghamba, E. G. S. 2007. Tooth and lip mutilation practices and associated tooth loss and oral mucosal lesions in the Makonde people of Southeast Tanzania. *East African Medical Journal*, 84(4): 183–187. DOI: 10.4314/eamj.v84i4.9523.
- Ferembach, D.; Schwidetzky, I.; Stloukal, M. 1980. Recommendations for age and sex diagnosis of skeletons. *Journal of Human Evolution*, 9(7): 517–549. DOI: 10.1016/0047-2484(80)90061-5.
- Finucane, B. C.; Manning, K.; Touré, M. 2008. Prehistoric dental modification in West Africa: early evidence from Karkarichinkat

- Nord, Mali. *International Journal of Osteoarchaeology*, 18(6): 632–640. DOI: 10.1002/oa.957.
- Gould, A. R.; Farman, A. G.; Corbii, D. 1984. Mutilations of the dentition in Africa: a review with personal observations. *Quintessence International*, 15(1): 89–94.
- Hillson, S. 2001. Recording dental caries in archaeological human remains. *International Journal of Osteoarchaeology*, 11(4): 249–289. DOI: 10.1002/oa.538.
- Hillson, S.; Bond, S. 1997. Relationship of enamel hypoplasia to the pattern of tooth crown growth: a discussion. *American Journal of Physical Anthropology*, 104(1): 89–103. DOI: 10.1002/(SICI)1096-8644(199709)104:1<89::AID-AJPA6>3.0.CO;2-8.
- Inoue, N.; Sakashita, R.; Inoue, M.; Kamegai, T.; Ohashi, K.; Katsivo, M. 1995. Ritual ablation of front teeth in modern and recent Kenyans. *Anthropological Science*, 103(3): 263–277. DOI: 10.1537/ase.103.263.
- Jones, A. 1992. Tooth mutilation in Angola. *British Dental Journal*, 173(5): 177–179.
- Lahon, D. 1999. *O Negro no coração do Império: uma memória a resgatar — Séculos XV-XIX*. Lisboa, Ministério da Educação/Casa do Brasil de Lisboa.
- Marques, A.; Bastos, M. 2013. Subsídios arqueológicos para a História da Igreja do Convento do Carmo (Lisboa). In: Arnaud, J. M.; Martins, A.; Neves C. (eds.) *Arqueologia em Portugal. 150 anos*. Lisboa, Associação dos Arqueólogos Portugueses: 1091–1101.
- Matos, V.; Santos, A. L. 2006. On the trail of pulmonary tuberculosis based on rib lesions: results from the Human Identified Skeletal Collection from the Museu Bocage (Lisbon, Portugal). *American Journal of Physical Anthropology*, 130(2): 190–200. DOI: 10.1002/ajpa.20309.
- McGladdery, H. 1950. Osteolytic bone syphilis. *Journal of Bone & Joint Surgery*, 32-B(2): 226–229.
- Milner, G. R.; Larsen, C. S. 1991. Teeth as Artifacts of Human Behavior: intentional mutilation and accidental modification. In: Kelley, M. A.; Larsen, C. S. (eds.) *Advances in dental anthropology*. New York, Wiley-Liss: 357–378.
- Mower, J. P. 1999. Deliberate ante-mortem dental modification and its implications in archaeology, ethnography and anthropology. *Papers from the Institute of Archaeology*, 10: 37–53. DOI: 10.5334/pia.137.
- Navega, D. S.; Coelho, C.; Vicente, R.; Ferreira, M. T.; Wasterlain, S.; Cunha, E. 2015. AnceSTrees: ancestry estimation with randomized decision trees. *International Journal of Legal Medicine*, 129(5): 1145–1153. DOI: 10.1007/s00414-014-1050-9.
- Ortner, D. J. 2008. Differential diagnosis of skeletal lesions in infectious disease. In: Pinhasi, R.; Mays, S. (eds.) *Advances in human paleopathology*. Chichester, John Wiley & Sons: 191–214.

- Ortner, D. J. 2011a. Human skeletal paleopathology. *International Journal of Paleopathology*, 1(1): 4–11. DOI: 10.1016/j.ijpp.2011.01.002.
- Ortner, D. 2011b. What skeletons tell us: the story of human paleopathology. *Virchows Archiv*, 459: 247–254. DOI: 10.1007/s00428-011-1122-x.
- Pereira, P. 1989. A igreja e convento do Carmo: do gótico ao revivalismo. In: Associação dos Arqueólogos Portugueses (ed.) *Comemoração dos 600 anos da fundação do Convento do Carmo em Lisboa: actas do colóquio comemorativo, Vila Nova de Ourém, 1989*. Lisboa, Associação dos Arqueólogos Portugueses: 87–113.
- Pindborg, J. J. 1969. Dental mutilation and associated abnormalities in Uganda. *American Journal of Physical Anthropology*, 31(3): 383–389. DOI: 10.1002/ajpa.1330310313.
- Quérel, C. 1990. *The history of syphilis*. Baltimore, The Johns Hopkins University Press.
- Redinha, J. 1974. *Etnias e culturas de Angola*. Luanda, Instituto de Investigação Científica de Angola.
- Reichart, P.; Creutz, U.; Scheifele, C. 2008. Dental mutilations and associated alveolar bone pathology in African skulls of the anthropological skull collection, Charité, Berlin. *Journal of Oral Pathology & Medicine* 37(1): 50–55. DOI: 10.1111/j.1600-0714.2007.00558.x.
- Rhine, S. 1990. Non-metric skull racing. In: Gill, G. W.; Rhine, S. (eds.) *Skeletal attribution of race: methods for forensic anthropology*. New Mexico, Maxwell Museum of Anthropology: 9–20.
- Santa Ana, J. 1745. *Chronica dos Carmelitas da antiga, e regular observancia nos reynos de Portugal, Algarves, e seus dominios, Tomo I*. Lisboa, Oficina dos Herdeiros de Antonio Pedrozo Galram.
- Santos, J. N. 1962. Mutilações dentárias em pretos de Moçambique. *Garcia de Orta* 10: 263–282.
- Sequeira, G. 1939. *O Carmo e a Trindade, Volume II*. Lisboa, Publicações Culturais da Câmara Municipal de Lisboa.
- Smith, B. H. 1984. Patterns of molar wear in hunter-gatherers and agriculturalists. *American Journal of Physical Anthropology*, 63(1): 39–56. DOI: 10.1002/ajpa.1330630107.
- Ubelaker, D. H. 1989. *Human skeletal remains: excavation, analysis and interpretation*. Washington, Taraxacum.
- Yang, K. L. 1940. Clavicle sign of late congenital syphilis: review of literature and report of six cases. *Archives of Dermatology and Syphilology*, 41(6): 1060–1065. DOI: 10.1001/archderm.1940.01490120062008.
- Waldron, T. 2009. *Palaeopathology. Cambridge Manuals in Archaeology*. Cambridge, Cambridge University Press.
- Wasterlain, S. N.; Neves, M. J., Ferreira, M. T. 2015. Dental modifications in a skeletal sample of enslaved Africans found at Lagos (Portugal). *International Journal of Osteoarchaeology*, 26(4): 621–632. DOI: 10.1002/oa.2453.