



## Transforaminal Endoscopic Approach to L5S1: Imaging Characterization of the Lower Lumbar Spine and Pelvis for Surgical Planning

José Miguel Sousa<sup>1,2</sup>, António Serrano<sup>2</sup>, Afonso Nave<sup>2</sup>, Vasco Mascarenhas<sup>3</sup>, Paulo Nogueira<sup>4</sup>, Joao Gamelas<sup>2</sup>, José Guimarães Consciência<sup>1,5</sup>

■ **OBJECTIVE:** To determine and compare pelvic and lumbosacral reference parameters with computed tomography in patients with low back pain (LBP) and a control group of asymptomatic patients to provide quantification data and morphological correlations for L5S1 transforaminal endoscopic approach (L5S1TEA).

■ **METHODS:** We prospectively evaluated 100 patients with LBP and a control group of 100 individuals, with spinopelvic computed tomography. We measured lumbopelvic and L5S1 transforaminal approach parameters: maximum approach angle (maxAA) and minimum approach angle (minAA) and skin incision (maxSI and minSI), iliac crest (IC) projection at intersection point (ICPi), distance between the projected intersection of maxAA with the ilium (ICi) and the posterior limit of the IC ( $\Delta$ ICi-ICpost), and distance between ICi and spinous process ( $\Delta$ ICi-SP).

■ **RESULTS:** Females and ICPi were increased in the LBP group: maxAA:  $48.38^\circ \pm 5.09^\circ$ ; minAA:  $32.5^\circ \pm 3.90^\circ$ ; maxSI:

$11.39 \pm 1.86$  cm; and minSI:  $8.30 \pm 1.48$  cm. Ilium intersection was increased in males; IC projection at the highest point (ICPh) was higher than ICPi; maxAA intersected the ilium in 28% and minAA in 1.5% of cases; ICi was positively correlated with facet angle, ICPh, and ICPi and negatively with  $\Delta$ ICi-SP.

■ **CONCLUSIONS:** Our results set preliminary reference values for L5S1TEA surgical planning. Besides higher ICPi, there were no differences between groups in measured parameters. Traditional IC height (ICPh) does not correspond to the point of intersection of the approach and is significantly higher than ICPi. ICi correlated to higher facet angle values, ICPh and ICPi grades, and lower  $\Delta$ ICi-SP. Potential conflict with the ilium is increased in the male population. IC is not impeditive of L5S1TEA in most cases.

### Key words

- Endoscopy
- High iliac crest
- L5S1
- Reference value
- Transforaminal

### Abbreviations and Acronyms

**$\Delta$ ICi-ICpost:** Distance between projected intersection of maximum approach angle with the ilium and posterior limit of the iliac crest

**$\Delta$ ICi-SP:** Distance between projected intersection of maximum approach angle with the ilium and the spinous process

**$\Delta$ ICi-SP:** Distance between the higher point of the iliac crest and the spinous process

**CT:** Computed tomography

**IC:** Iliac crest

**ICi:** Projected intersection of maximum approach angle with the ilium

**ICi:** Higher point of the iliac crest

**ICPh:** Iliac crest projection on lumbar spine at highest point

**ICPi:** Iliac crest projection at intersection point

**ICpost:** Posterior limit of the iliac crest

**IELD:** Interlaminar endoscopic lumbar discectomy

**L5S1TEA:** L5S1 transforaminal endoscopic approach

**LBP:** Low back pain

**maxAA:** Maximum approach angle

**maxSI:** Maximum skin incision

**maxICi:** Maximum ilium intersection

**MD:** Mean difference

**minAA:** Minimum approach angle

**minSI:** Minimum skin incision

**PI:** Pelvic incidence

**SAP:** Superior articular process

**SP:** Spinous process

**TEA:** Transforaminal endoscopic approach

**TELD:** Transforaminal endoscopic lumbar discectomy

**trans-SAP:** Transsuperior articular process

From the <sup>1</sup>CHRC, NOVA Medical School, Faculdade de Ciências Médicas, NMS, FCM, Universidade NOVA de Lisboa; <sup>2</sup>Centro Hospitalar Lisboa Ocidental, Orthopaedics Department; <sup>3</sup>Musculoskeletal Imaging Unit, Imaging Center, Radiology Department, Hospital da Luz; <sup>4</sup>Instituto de Medicina Preventiva e Saúde Pública, Faculdade de Medicina, Universidade de Lisboa, Área Disciplinar Autónoma de Bioestatística (Laboratório de Biomatemática); and <sup>5</sup>Centro Hospitalar Lisboa Ocidental, Pre and Pos Graduation Department, Lisbon, Portugal

To whom correspondence should be addressed: José Miguel Sousa, M.D.

[E-mail: [josemiguelsousa.spine@gmail.com](mailto:josemiguelsousa.spine@gmail.com)]

Citation: *World Neurosurg.* (2023) 175:e809-e817.

<https://doi.org/10.1016/j.wneu.2023.04.026>

Journal homepage: [www.journals.elsevier.com/world-neurosurgery](http://www.journals.elsevier.com/world-neurosurgery)

Available online: [www.sciencedirect.com](http://www.sciencedirect.com)

1878-8750/© 2023 The Author(s). Published by Elsevier Inc. This is an open access article under the CC BY-NC-ND license (<http://creativecommons.org/licenses/by-nc-nd/4.0/>).

## INTRODUCTION

**T**ransforaminal endoscopic approach (TEA) to the spine is an established surgical technique with a wide range of applications, from addressing disc herniations and foraminal and lateral recess degenerative pathology to providing access to endoscopic-assisted lumbar interbody fusion techniques.<sup>1</sup>

In L5/S1, TEA is known for its challenging singularity. The iliac crest (IC), foraminal and facet joints morphology, the L5 dorsal root ganglion anatomy, and the slope of the disk space have been pointed out as some of the limiting factors.<sup>1-3</sup> Some groups do not recommend L5/S1 transforaminal endoscopic approach (L5/S1TEA) due to impending pelvic structures, and others favor interlaminar endoscopic lumbar discectomy (IELD) due to a broader interlaminar space, decreased radiation time, and decreased operative time. However, despite the latter, transforaminal endoscopic lumbar discectomy (TELD) has shown similar clinical outcomes and safety compared with IELD<sup>2,4-6</sup> and was preferred for foraminal or extraforaminal disc herniations<sup>5</sup> and also shoulder type, centrally located, and recurrent disc herniations.<sup>4</sup> In a randomized control trial comparing TELD and IELD in L5/S1 under local anesthesia, TELD was favored due to less operative time, postoperative bed rest time, and complications, showing less intraoperative pain and a higher postoperative satisfaction rate.<sup>7</sup> Despite the reported increase in radiation and operative times in L5/S1TEA, safety and reliable clinical outcomes have been established.<sup>3,4,7,8</sup> Increased development and availability of navigation technology applied to spine endoscopy will probably minimize the downside of radiation exposure and decrease operation time by allowing navigated placement of the initial guidewire.

Several studies reported on Kambin's triangle<sup>9,10</sup> dimensions, distance to exiting nerve root, and risk of injury. L5/S1 has been shown to have the largest Kambin's triangle area among the lumbar levels, both in the superior articular process (SAP) retained and the SAP removed cohorts, even though a decrease in L4/L5 and L5/S1 Kambin's triangle area was shown to correlate with degenerative disc disease or spondylolisthesis, and therefore an extended foraminotomy or transsuperior articular process (trans-SAP) approach is advised in such cases.<sup>11-13</sup> On the other hand, despite being pointed out as a potential limiting factor, there is scarce literature on the morphology of the pelvis and IC and its correlation with L5/S1 transforaminal trajectory. IC height is usually measured based on the sagittal projection of its highest point in the lumbar spine on standing lateral X-rays, which in most cases does not correspond to the effective point of intersection with the transforaminal access route.<sup>3,14</sup> Analysis of computed tomography (CT) images might allow a better understanding of the anatomy and more precise surgical planning.

We aim to determine and compare the pelvic and lumbosacral reference parameters with CT in patients with low back pain (LBP) and a control group of asymptomatic patients to provide quantification data and morphological correlations for L5/S1TEA. In addition, we expect to contribute to the surgical planning and execution of TEA to L5/S1 with relevant information.

## MATERIAL AND METHODS

### Study Population

This study was approved by the review board and the ethics committee of our academic and hospital institutions (nr.68/2019/CEFCM and CES/04/2020/ME). All participants provided written informed consent. Consecutive symptomatic patients undergoing lumbosacral CT for chronic LBP (minimum 6 months) and individuals undergoing pelvic CT for thoracic, abdominal, and urogenital indications were prospectively recruited from August 2021 to August 2022. Only participants over 18 years old were considered. Individuals with previous spine or pelvic fractures, spine tumors or infectious diseases, spine surgery, congenital spinopelvic anomalies, or hip replacement surgery were excluded. Individuals with CT signs of the previously mentioned exclusion criteria were also excluded. Participants with LBP or radiating pain to the lower limbs in the previous 6 months were excluded from the control group. Overall, 200 individuals were eligible for analysis (**Figure 1**).

### CT Imaging

In either group, CT imaging was performed using a Somatom Force 192-slice and a Somatom Go TOP 64-slice CT scanners (Siemens, Erlangen, Germany). Patients' position was standardized in supine with knees extended and lower limbs parallel in neutral rotation.<sup>15,16</sup> The lower lumbar spine and pelvis were reconstructed from the superior end plate of L3 to the lesser trochanters, with a 1.5 mm thickness.

### Measurements

Digital Imaging and Communications in Medicine images were uploaded for analysis using OsiriX MD (Pixmeo SARL©, Bern, Switzerland),<sup>17</sup> previously certified and validated for clinical use. For each subject, images were initially standardized and reformatted in coronal, axial, and sagittal planes to correct tilt, rotation, and pelvic obliquity, assuring the alignment of the femoral heads. Data collected in the axial plane were measured in a slice parallel and tangential to the S1 superior end plate in the sagittal plane.

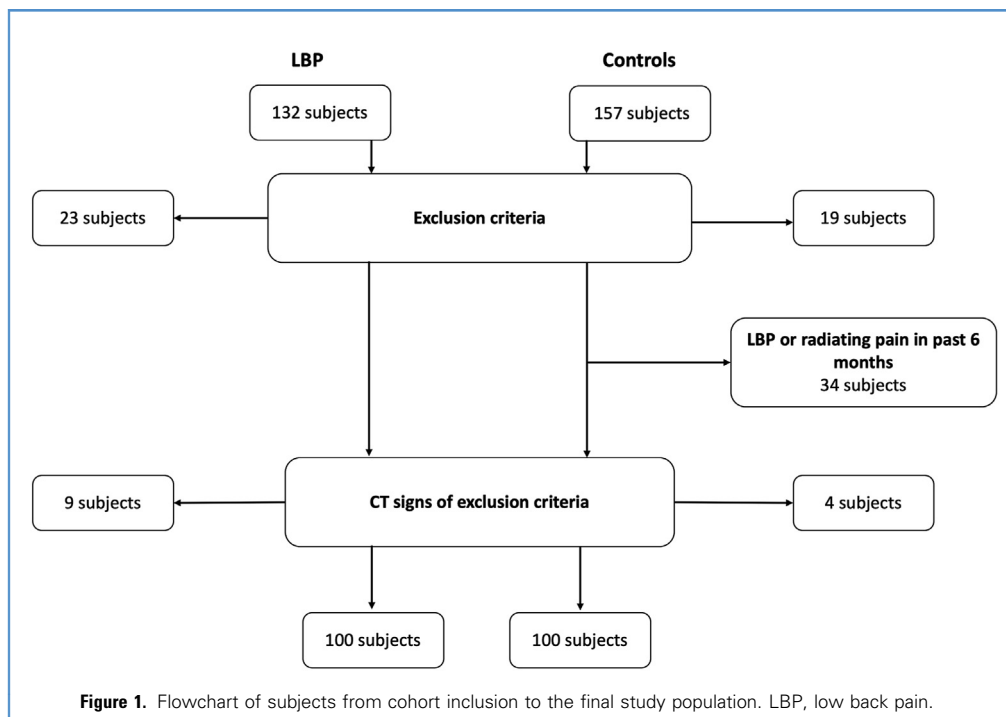
Parameters were measured by 2 authors (J.M.S. and A.S.) and accessed for interobserver reliability. For intraobserver reliability, measurements were repeated at least 2 weeks apart.

Pelvic and lumbosacral anatomic parameters were measured as follows:

- 1) Pelvic incidence (PI), pelvic tilt, and sacral slope<sup>18,19</sup>; 2) iliac crest projection in the lumbar spine at its highest point (ICPh) (**Figure 2**); and 3) L5/S1 facet angle (**Figure 3**).

The following L5/S1 approach parameters were defined:

- 1) Maximum approach angle (maxAA), defined as the angle between the midline and a vector tangential to the lateral aspect of S1 superior articular process (SAP) crossing the center of the disc space; 2) minimum approach angle (minAA), defined as the angle between the midline and a vector tangential to the lateral aspect of S1 SAP crossing the most anterior point of the disc space; 3) working angle (workAA), defined as the angle between the



tangential vectors of maxAA and minAA; 4) maximum skin incision and minimum skin incision (maxSI and minSI), defined as the distance between the midline and the point of intersection of maxAA and minAA tangential vectors with the skin (Figure 3); 5) Maximum ilium intersection (maxICi) and minimum ilium intersection (minICi), determined by the intersection or not of the ilium by the tangential vectors of maxAA and minAA, respectively; 6) iliac crest projection in the lumbar spine at its intersection point with the maxAA (ICPi); 7) distance between the intersection point to the posterior limit of the iliac crest ( $\Delta$ ICi-ICpost) (Figure 2); and 8) distance between the higher point of the iliac crest (ICh) and iliac crest intersection point with the maxAA (ICi) to the spinous process (SP) ( $\Delta$ ICh-SP and  $\Delta$ ICi-SP).

Lumbosacral anatomical parameters and L5/S1 approach parameters were registered bilaterally.

### Statistical Analysis

The means and standard deviation were calculated for the measured parameters. Paired t test was used to determine the statistical differences between continuous variables of both groups and subgroup analysis. The  $\chi^2$  test was used to determine statistical differences for nominal and ordinal variables. To evaluate the correlation between parameters, the Pearson correlation coefficient was used for continuous variables and Spearman for ordinal variables. Binary logistic regression was used to assess if the variables that correlated to maxICi independently modeled well the variation of this parameter.

When binary logistic regression for maxICi was used, a good model fit was obtained using the variables facet angle, ICPh, ICPi, and  $\Delta$ ICi-SP independently.

Statistical significance was set at  $P$  value  $< 0.05$ . Statistical analyses were performed using dedicated software (SPSS 26.0, IBM Corporation, Armonk, NY, USA).<sup>20</sup>

The interclass correlation coefficient was used to assess intra-observer and interobserver reliability of the measurements. Values of 0.75 to 0.90 and 0.90 to 1.00 were considered good and excellent, respectively.<sup>21</sup>

## RESULTS

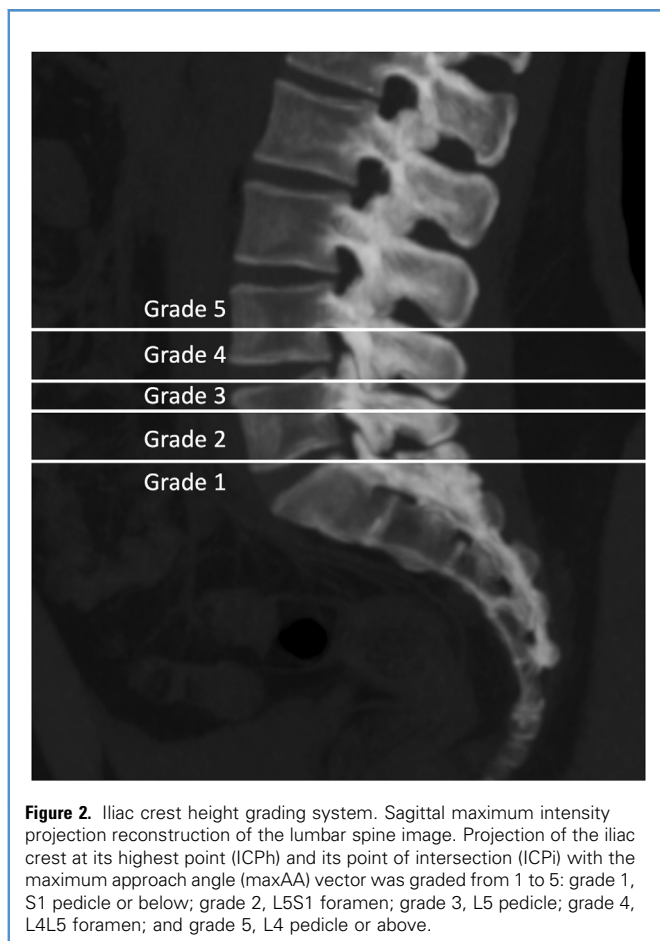
### Baseline Characteristics

Images were obtained from 200 participants. The mean age was  $56.21 \pm 16.45$  years (18–83) and  $57.97 \pm 14.46$  years (19–87) for the LBP and control groups, respectively. The proportion of females was significantly increased in the LBP group ( $P$  value = 0.033) (Table 1). ICPi was significantly increased in the LBP group ( $P$  value = 0.005 and  $P$  value = 0.01 on the right and left sides, respectively).

There was no difference in the remaining lumbosacral anatomic parameters and L5/S1 approach parameters measured between the LBP group and the control group.

### Lumbosacral Anatomic Parameters

The overall mean PI was  $48.58 \pm 10.46^\circ$  (24.41–83.50), the mean sacral slope was  $36.35 \pm 8.00^\circ$  (13.47–58.64), and the mean pelvic tilt was  $12.23 \pm 6.03$  (0.07–28.43).



**Figure 2.** Iliac crest height grading system. Sagittal maximum intensity projection reconstruction of the lumbar spine image. Projection of the iliac crest at its highest point (ICPh) and its point of intersection (ICPi) with the maximum approach angle (maxAA) vector was graded from 1 to 5: grade 1, S1 pedicle or below; grade 2, L5/S1 foramen; grade 3, L5 pedicle; grade 4, L4/L5 foramen; and grade 5, L4 pedicle or above.

ICPh was above the L5 pedicle (grades 4 and 5) in 78% of the studied population. The mean L5/S1 facet angle was  $48.81 \pm 9.60^\circ$  ( $25.14$ – $80.97$ ).

### L5/S1 Approach Parameters

The overall measurements of L5/S1 approach parameters are portrayed in **Table 2**.

The maxAA ranged from  $27.79$  to  $63.20^\circ$  (mean,  $48.38 \pm 5.09^\circ$ ), and the minAA ranged from  $18.72$  to  $43.46^\circ$  (mean,  $32.50 \pm 3.90^\circ$ ). The mean working angle was  $16.24 \pm 2.91^\circ$  ( $9.08$ – $30.73$ ).

The mean maxSIP was  $11.39 \pm 1.86$  cm ( $5.05$ – $17.13$ ), and the mean minSIP was  $8.30 \pm 1.48$  cm ( $3.52$ – $12.18$ ). The mean difference (MD) between maxSIP and minSIP was  $3.08 \pm 0.81$  cm ( $1.14$ – $8.04$ ).

The maxAA intersected the ilium in 112 projections, while the minAA intersected the ilium in 6 projections ( $N = 400$ ). In most of the population with ICPh grade 5, there was an intersection of the ilium by the maxAA in 67.3%, and in the population with ICPh grade 4 and grade 3, it was observed in 29.0% and 3.5% of the projections, respectively (**Table 3**).

The distance of the maximum projected iliac crest intersection to the posterior edge of the iliac crest ( $\Delta$ ICi-ICpost) was  $0.67 \pm 0.39$  ( $0$ – $2.21$ ) cm.

The mean  $\Delta$ ICi-SP and  $\Delta$ ICi-SP were  $8.59 \pm 0.86$  cm ( $6.15$ – $11.48$ ) and  $6.15 \pm 0.74$  cm ( $4.29$ – $8.80$ ), respectively. The MD between  $\Delta$ ICi-SP and  $\Delta$ ICi-SP was  $2.44 \pm 0.98$  cm ( $0$ – $5.89$ ) (**Table 2**).

The IC projection in the lumbar spine was significantly increased at its highest point compared to the projection at its intersection point ( $P$  value =  $0.011$ ).

### Correlations

The correlations between the main lumbosacral anatomic measurements and L5/S1 approach parameters are summarized in **Table 4**.

The PI had a positive correlation with ICPh and ICPi ( $P$  value <  $0.001$ ), a negative correlation with  $\Delta$ ICi-SP ( $P$  value =  $0.034$ ), and no correlation with facet angle, maxICi, or  $\Delta$ ICi-SP.

The maxICi had a positive correlation with facet angle, ICPh, and ICPi ( $P$  value <  $0.001$ ), a negative correlation with  $\Delta$ ICi-SP ( $P$  value <  $0.001$ ), and no correlation with PI nor  $\Delta$ ICi-SP.

The facet angle had a positive correlation with maxICi ( $P$  value <  $0.001$ ), a negative correlation with  $\Delta$ ICi-SP ( $P$  value =  $0.014$ ), and no correlation with PI, ICPh, ICPi, or  $\Delta$ ICi-SP.

When binary logistic regression for maxICi was used, a good model fit was obtained using the variables facet angle, ICPh, ICPi, and  $\Delta$ ICi-SP independently.

### Subgroup Analysis

We performed subgroup analysis according to sex. In female participants, there was a significant increase in maxSI and minSI ( $P$  value =  $0.012$  and  $0.014$ , respectively). In male participants, there was a significant increase in maxICi ( $P$  value <  $0.001$ ), minimum ilium intersection ( $P$  value =  $0.008$ ), ICPh ( $P$  value <  $0.001$ ), and ICPi ( $P$  value <  $0.001$ ).

We also performed subgroup analysis according to the ilium intersection occurring in the projection of both maxAA and minAA or only in the maxAA projected. The ICi-ICpost distance was significantly increased when the projection of the minAA intersected the ilium (MD,  $0.62$ ; 95% CI,  $0.32$ ,  $0.93$ ;  $P$  value <  $0.001$ ) (**Table 5**).

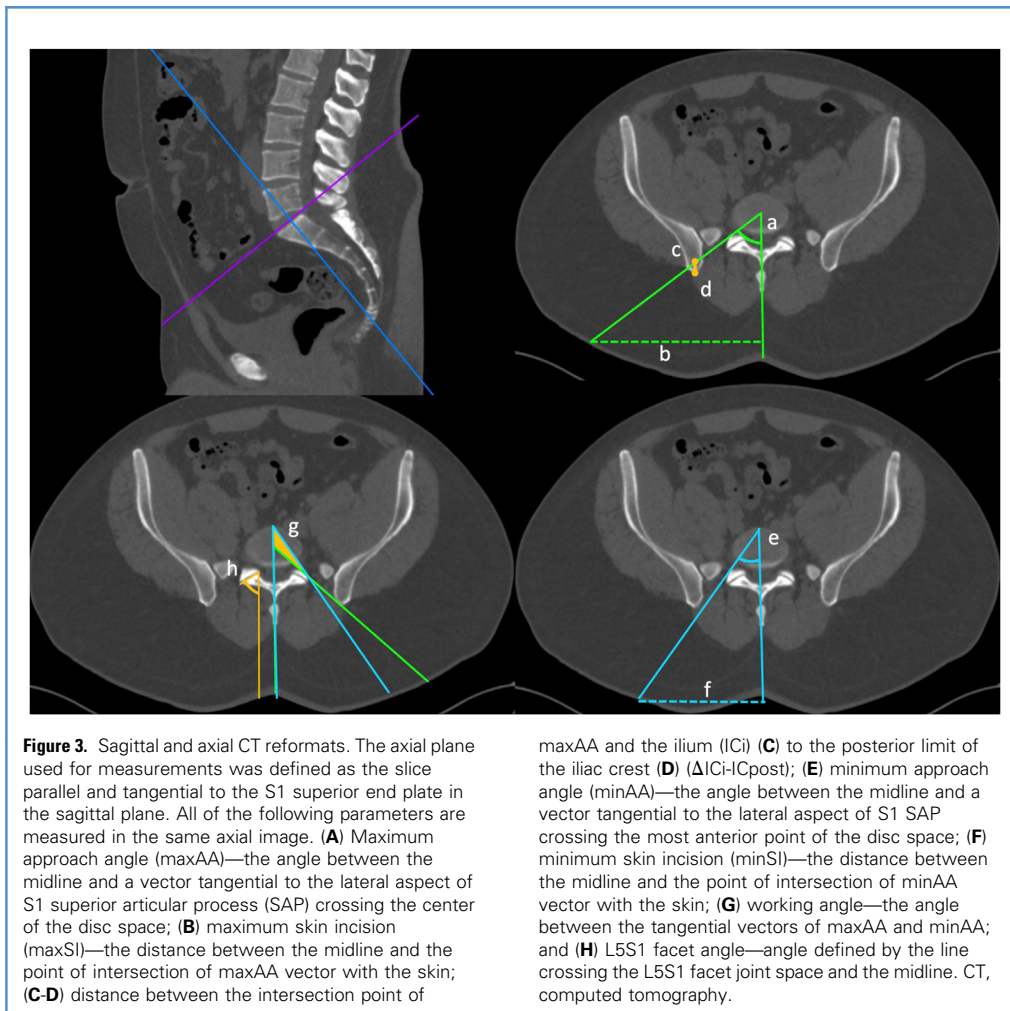
### Reliability

Interobserver reliability was good in  $\Delta$ ICi-SP and  $\Delta$ ICi-SP. Intraobserver reliability was good in  $\Delta$ ICi-SP. Interobserver and intraobserver reliabilities were excellent in all other measurements.

### DISCUSSION

Preoperative planning is critical for any surgical procedure. Identifying the main anatomic structures will determine the feasibility of a standard transforaminal endoscopic spine access or the need to perform an extended foraminoplasty, a trans-SAP approach, a transiliac approach, or to convert to another surgical option. Besides the exiting nerve root trajectory and foraminal morphology, other characteristics must be considered in L5/S1 since the IC and lumbopelvic anatomy may cause additional constraints for a TEA.<sup>1-3,8</sup>

In the studied population, there was a higher frequency of females in the LBP group, which is in accordance with previous



reports.<sup>22,23</sup> Despite a significant increase of ICPI in the LBP group, there were no other significant differences in the morphometric and L5S1 approach parameters between both groups.

Subgroup analysis, according to sex, revealed that the level of the IC was significantly increased in males, either at its highest point or at the point of intersection with the ideal projected track

to L5S1. Crossing of the ilium by both projected access tracks to the foramen was also more frequent in the male population, showing a higher chance of conflict for an L5S1 transforaminal approach than for female patients. On the other hand, despite females having a statistically significant increase in the distance between the skin incision and the midline, the MD was inferior to 0.5 cm, which may not be relevant in clinical practice. These findings correlate to the previously described anatomy of the pelvis and its distinction between male and female populations, namely the relatively longer and narrower pelvis of males, with higher reaching ICs.<sup>24</sup>

Our results show that the ICPh is significantly increased compared to the ICPI, even though both projections have a positive correlation. While the ICPh was above the L5 pedicle (grade 4 or 5) in 77.8% of the measurements, the ICPI was above the L5 pedicle in only 27.3%. Overall, 28% of the measures conflicted with the ilium when considering an ideal approach to the center of the disc space of L5S1. When considering the minAA, only 6 cases conflicted with the ilium, corresponding to 1.9% of cases with an ICPh grade 4 or 5. The mean distance to the posterior aspect of the

**Table 1.** Distribution by Sex in Low Back Pain Group and Control Group

	Female	Male	Total
LBP	61	39	100
Control group	46	54	100
Total	107	93	200

LBP, low back pain.

**Table 2.** L5/S1 Approach Parameters

Parameter	Mean $\pm$ SD (Range)
maxAA	48.38 $\pm$ 5.09 (27.79–63.20)
minAA	32.50 $\pm$ 3.90 (18.72–43.46)
maxSI	11.39 $\pm$ 1.86 (5.05–17.13)
minSI	8.30 $\pm$ 1.48 (3.52–12.18)
$\Delta$ IC <sub>h</sub> -SP	8.59 $\pm$ 0.86 (6.15–11.48)
$\Delta$ IC <sub>i</sub> -SP	6.15 $\pm$ 0.74 (4.29–8.80)

maxAA, maximum approach angle; minAA, minimum approach angle; maxSI, maximum skin incision; minSI, minimum skin incision;  $\Delta$ IC<sub>h</sub>-SP, distance between the higher point of the iliac crest (IC<sub>h</sub>) and the spinous process (SP);  $\Delta$ IC<sub>i</sub>-SP, iliac crest intersection point with the maxAA (IC<sub>i</sub>) to the spinous process (SP); SD, standard deviation.

IC of the maxAA was 0.64 cm when only the ideal track crossed the ilium. In comparison, the mean distance increased to 1.26 cm in cases where both maxAA and minAA crossed the ilium. These findings suggest that almost one third of the cases could conflict with the IC considering the defined ideal transforaminal track to the disc space. However, only in a small percentage (1.5%) of all cases was it impossible to determine a trajectory that allowed transforaminal access aiming at the most anterior end of the disc space. Considering that the lumbosacral junction has some residual plasticity, it seems reasonable that the mean distance to the posterior end of the IC can be overcome in most cases when only the maxAA crosses the IC. Also, in most cases, an extended foraminotomy or a trans-SAP approach will probably allow to overcome the limitations that the IC might impose on an L5/S1TEA.<sup>11-13</sup> Ultimately, in the residual cases where an L5/S1TEA is not feasible, other alternatives can be used, namely, a transiliac transforaminal approach, an ipsilateral interlaminar approach, a contralateral interlaminar approach, or a complete facetectomy with supplemental fixation, depending on the specificity of each case and the surgeons' discretion. The presented results clearly demonstrate that current standing X-ray grading systems are unsuited to measure the IC height where it actually could interfere with an L5/S1TEA.<sup>3,8</sup>

Besides a higher frequency in males, the intersection of the ilium by the maxAA correlated with higher facet angles, ICPh, and IC<sub>Pi</sub> grades and a lower  $\Delta$ IC<sub>i</sub>-SP. These anatomic features seem to influence the possibility of IC constraints and should be considered in preoperative planning. PI also had a positive correlation with ICPh and IC<sub>Pi</sub> and a negative correlation with the  $\Delta$ IC<sub>i</sub>-SP.

Based on the studied population, the ideal mean approach to L5/S1 is around 48° in the axial plane, with a mean working angle of 16°. Angulation of endoscopic cameras furthers the field of vision and action with an actual reach beyond the mentioned working angle. This allows addressing foraminal and lateral recess pathology in most cases.

The mean distance of the skin incision to the midline is around 11.39 cm to access the center of the disc space, while it may decrease to 8.30 cm when planning an approach to the foraminal or paramedian space. These results substantiate and provide evidence to support the skin incision distance to the midline previously used to approach L5/S1 for disc herniations or stenotic pathology and endoscopic-assisted transforaminal interbody fusion.<sup>13,25</sup>

Despite the information described, individual imaging must be accessed preoperatively for each patient. The traditional measurements used to determine the skin incision and approach trajectory in a 2-dimensional setting (Figure 4) cannot provide detailed and accurate information on the potential limitations of an L5/S1 endoscopic transforaminal access. The methodology used in this paper allows for planning skin incision, identifying possible constraints for transforaminal L5/S1 access, planning eventual extended foraminoplasty, a trans-SAP or transiliac approach, or the need to be prepared to convert or choose *ab initio* an ipsilateral or contralateral interlaminar approach according to the pathology to be treated.

### Strengths and Limitations

Our results were derived from a limited sample of 200 individuals and may not be extrapolated for the general population. Furthermore, LBP may be associated with several factors, namely disc, end plate, facet, and muscle changes. However, our study aimed to identify differences in the regional lumbosacral morphology of patients with chronic LBP that would interfere with the

**Table 3.** Iliac Crest Height and Intersection of the Ilium by the Projected Vectors of the Approach Angles, According to IC Grading System

Grade	ICPh	IC <sub>Pi</sub>	Maximum Ilium Intersection	Minimum Ilium Intersection	No IC <sub>i</sub>
5	49	3	33	2	14
4	262	106	76	4	182
3	86	249	3	0	83
2	3	42	0	0	3
1	0	0	0	0	0
Total	400	400	112	6	282

ICPh, iliac crest highest point projection in the lumbar spine; IC<sub>Pi</sub>, iliac crest intersection point with maximum approach angle vector projection in the lumbar spine; IC<sub>i</sub>, iliac crest intersection point with maximum approach angle vector; IC, iliac crest.

**Table 4.** Correlation Between Lumbopelvic Parameters and L5/S1 Approach Parameters

	PI	Facet Angle	Maximum Ilium Intersection	ICPh	ICPi	ΔICh-SP	ΔICi-SP
PI		0.081* (0.106)	−0.015† (0.767)	0.203† <b>(&lt;0.001)</b>	0.361† <b>(&lt;0.001)</b>	−0.051* (0.311)	−0.106* <b>(0.034)</b>
Facet angle	0.081* (0.106)		0.303† <b>(&lt;0.001)</b>	−0.005† (0.924)	0.026† (0.610)	−0.122* <b>(0.014)</b>	0.004* (0.937)
Maximum ilium intersection	−0.015† (0.767)	0.303† <b>(&lt;0.001)</b>		0.393† <b>(&lt;0.001)</b>	0.240† <b>(&lt;0.001)</b>	−0.012† (0.813)	−0.216† <b>(&lt;0.001)</b>
ICPh	0.203† <b>(&lt;0.001)</b>	−0.005† (0.924)	0.393† <b>(&lt;0.001)</b>		0.458† <b>(&lt;0.001)</b>	0.081† (0.104)	−0.312† <b>(&lt;0.001)</b>
ICPi	0.361† <b>(&lt;0.001)</b>	0.026† (0.610)	0.240† <b>(&lt;0.001)</b>	0.458† <b>(&lt;0.001)</b>		−0.005† (0.920)	−0.208† <b>(&lt;0.001)</b>
ΔICh-SP	−0.051* (0.311)	−0.122* <b>(0.014)</b>	−0.012† (0.813)	0.081† (0.104)	−0.005† (0.920)		0.232* <b>(&lt;0.001)</b>
ΔICi-SP	−0.106* <b>(0.034)</b>	0.004* (0.937)	−0.216† <b>(&lt;0.001)</b>	−0.312† <b>(&lt;0.001)</b>	−0.208† <b>(&lt;0.001)</b>	0.232* <b>(&lt;0.001)</b>	

Pearson correlation coefficient was used for continuous variables and Spearman for ordinal variables; (*P* value). Bold indicates *P* value < 0.05.

ICPh, iliac crest highest point projection in the lumbar spine; ICPi, iliac crest intersection point with maximum approach angle vector projection in the lumbar spine; ΔICh-SP, distance between the higher point of the iliac crest (IC<sub>h</sub>) and the spinous process (SP); ΔICi-SP, iliac crest intersection point with the maxAA (IC<sub>i</sub>) to the spinous process (SP); PI, pelvic incidence.

\*Pearson correlation coefficient

†Spearman

transforaminal L5/S1 approach. For patient selection, our focus was on the symptoms, not the LBP's etiology. Nonetheless, we included several patients and participants with conditions that could confound the results.

The global spinal alignment was not evaluated, as conventional CT imaging is not very useful for analyzing spine balance since patients are in a supine position.<sup>26</sup> Nevertheless, to our knowledge, this is the first study to analyze specific pelvic and lumbosacral parameters and their correlations with transforaminal access to L5/S1. Even so, global spinal alignment remains a good asset for investment in future research. Also, this study is the most comprehensive database providing data for setting preliminary reference access angles and skin incision

planning values, IC height at IC<sub>i</sub>, and potential conflict to an L5/S1 transforaminal approach.

Other limitations relate to the potentially time-consuming analysis compared to simple stand X-ray observation and radiation exposure, though these parameters are easily transposed to 3-dimensional magnetic resonance imaging. Current results will benefit with further correlation to surgical approach in clinical practice.

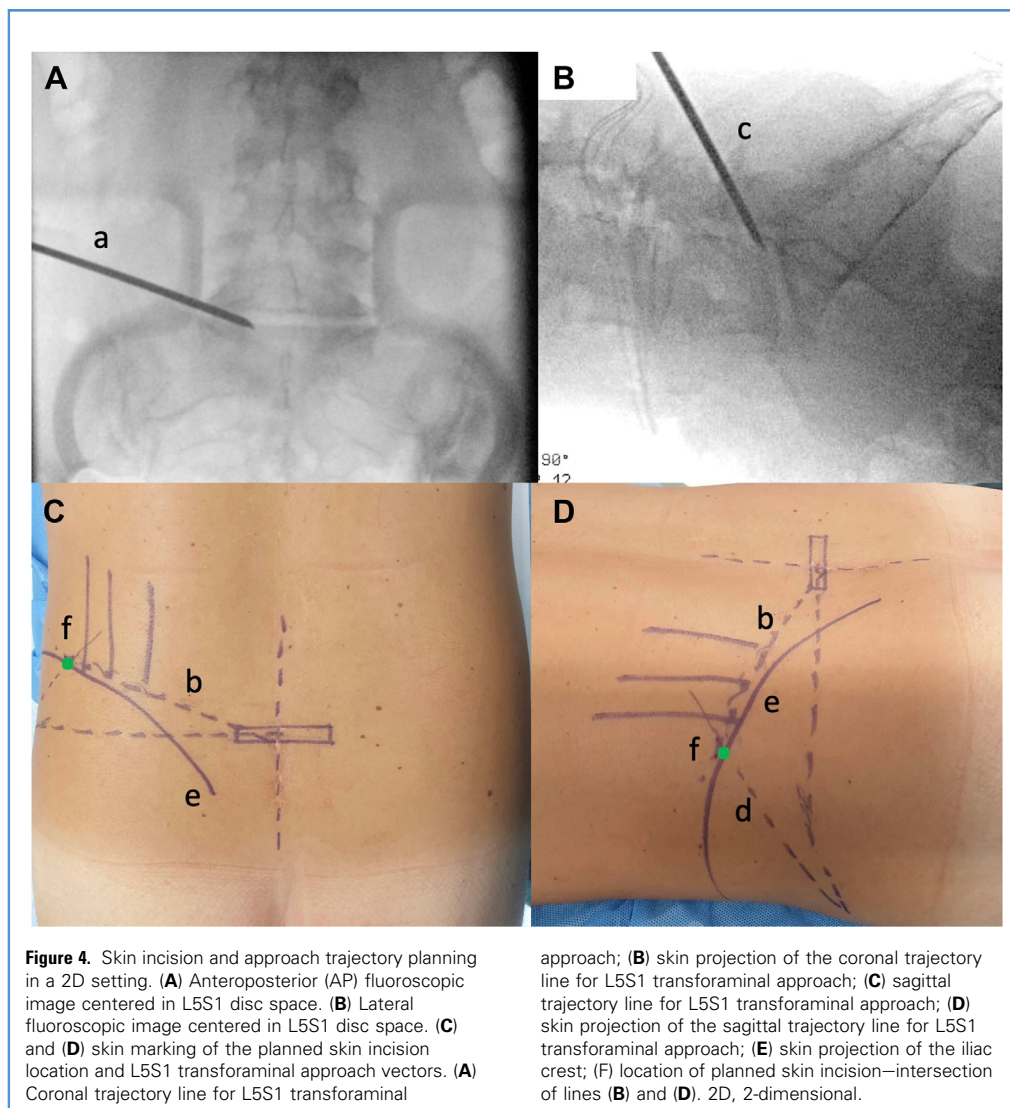
## CONCLUSIONS

Deep understanding and knowledge of patient anatomy will increase surgical procedures' safety, accuracy, and effectiveness. Our results comprehensively characterize lumbosacral morphology for L5/S1 transforaminal access, setting preliminary reference values for access and working angles, its correlation to the IC, and reference values for skin incision planning. Intersection with the ilium correlates not only to the IC height at different points but also with higher facet joint angles and decreased intersection point distance to the SP. IC height was also shown to increase with higher PI. As traditionally measured by the projection of its highest point, the IC height does not correspond to the potential point of conflict with transforaminal access to L5/S1, and only in a small percentage of cases will the IC eventually prevent this approach. Due to the pelvic anatomic differences between genders, potential conflict with the ilium is increased in the male population. Despite a significant increase in ICP<sub>i</sub>, LBP participants

**Table 5.** Subgroup Analysis According to Ilium Intersection by Both Maximum and Minimum Approach Angles or Only in the Maximum Approach Angle Projected

Subgroup	Minimum Ilium Intersection + Maximum Ilium Intersection	Maximum Ilium Intersection Only
n	6	106
Mean ± SD (range)	1.26 ± 0.52 (0.72–2.21)	0.64 ± 0.35 (0.00–1.67)

SD, standard deviation.



had overlapping morphometric and L5/S1 approach parameters to the control group.

#### CRedit AUTHORSHIP CONTRIBUTION STATEMENT

**José Miguel Sousa:** Conceptualization, Data curation, Formal analysis, Funding acquisition, Investigation, Methodology, Project administration, Resources, Software, Validation, Visualization, Writing — original draft. **António Serrano:** Data curation, Writing

— review & editing. **Afonso Nave:** Conceptualization, Validation, Writing — review & editing. **Vasco Mascarenhas:** Conceptualization, Methodology, Validation, Writing — review & editing. **Paulo Nogueira:** Formal analysis, Methodology, Writing — review & editing. **João Gamelas:** Conceptualization, Project administration, Writing — review & editing. **José Guimarães Consciência:** Conceptualization, Methodology, Project administration, Visualization, Writing — review & editing.

#### REFERENCES

- Sousa JM, Ribeiro H, Silva JL, Nogueira P, Consciência JG. Clinical outcomes, complications and fusion rates in endoscopic assisted intraforaminal lumbar interbody fusion (iLIF) versus minimally invasive transforaminal lumbar interbody fusion (MI-TLIF): systematic review and meta-analysis. *Sci Rep.* 2022;12:2101.
- Chen J, Jing X, Li C, Jiang Y, Cheng S, Ma J. Percutaneous endoscopic lumbar discectomy for L5/S1 lumbar disc herniation using a transforaminal approach versus an interlaminar approach: a systematic review and meta-analysis. *World Neurosurg.* 2018;116:412-420.e2.
- Choi KC, Park C-K, Choi KC, Park CK. Percutaneous endoscopic lumbar discectomy for L5-S1 disc herniation: consideration of the relation between the iliac crest and L5-S1 disc. *Pain Physician.* 2019;22:E241-E244.
- Choi KC, Kim J-S, Ryu K-S, Kang BU, Ahn Y, Lee S-H. Percutaneous endoscopic lumbar discectomy for L5-S1 disc herniation: transforaminal

- versus interlaminar approach. *Pain Physician*. 2013;16:547-556.
5. Mo X, Shen J, Jiang W, et al. Percutaneous endoscopic lumbar discectomy for axillar herniation at L5-S1 via the transforaminal approach versus the interlaminar approach: a prospective clinical trial. *World Neurosurg*. 2019;125:e508-e514.
  6. Jitpakdee K, Liu Y, Kotheeranurak V, Kim JS. Transforaminal versus interlaminar endoscopic lumbar discectomy for lumbar disc herniation: a systematic review and meta-analysis. *Glob Spine J*. 2023;13:575-587.219256822211205.
  7. Chen Z, Wang X, Cui X, Zhang G, Xu J, Lian X. Transforaminal versus interlaminar approach of full-endoscopic lumbar discectomy under local anesthesia for L5/S1 disc herniation: a randomized controlled trial. *Pain Physician*. 2022;25: E1191-E1198.
  8. Patgaonkar P, Datar G, Agrawal U, et al. Supra-iliac versus transiliac approach in transforaminal endoscopic discectomy at L5-S1: a new surgical classification of L5—iliac crest relationship and guidelines for approach. *J Spine Surg*. 2020;6: S145-S154.
  9. Kambin P, Gellman H. Percutaneous lateral discectomy of the lumbar spine a preliminary report. *Clin Orthop Relat Res*. 1983;174:127-132.
  10. Kambin P. Arthroscopic microdiscectomy. *Mt Sinai J Med*. 1991;58:159-164.
  11. Waguia Kouam R, Tabarestani TQ, Sykes DAW, et al. How dimensions can guide surgical planning and training: a systematic review of Kambin's triangle. *Neurosurg Focus*. 2023;54:E6.
  12. Hurday Y, Xu B, Guo L, et al. Radiographic measurement for transforaminal percutaneous endoscopic approach (PELD). *Eur Spine J*. 2017;26: 635-645.
  13. Hasan S, White-Dzuro B, Barber JK, Wagner R, Hofstetter CP. The endoscopic trans-superior articular process approach: a novel minimally invasive surgical corridor to the lateral recess. *Oper Neurosurg*. 2020;19:E1-E10.
  14. Yang J-S, Re: Choi KC, Park CK. Percutaneous endoscopic lumbar discectomy for L5-S1 disc herniation: consideration of the relation between the iliac crest and L5-S1 disc. *Pain Physician*. 2019; 22:E241-E244.
  15. İplikçioglu AC, Karabağ H. Validity and reliability of spinopelvic parameters measured on computed tomography. *Int J Spine Surg*. 2022;16:875-880.
  16. Mascarenhas VV, Rego P, Dantas P, Gaspar A, Soldado F, Consciência JG. Cam deformity and the omega angle, a novel quantitative measurement of femoral head-neck morphology: a 3D CT gender analysis in asymptomatic subjects. *Eur Radiol*. 2017;27:2011-2023.
  17. Rosset A, Spadola L, Ratib O. OsiriX: an open-source software for navigating in multidimensional DICOM images. *J Digit Imaging*. 2004;17: 205-216.
  18. Legaye J, Duval-Beaupère G, Marty C, Hecquet J. Pelvic incidence: a fundamental pelvic parameter for three-dimensional regulation of spinal sagittal curves. *Eur Spine J*. 1998;7:99-103.
  19. Lee CM, Liu RW. Comparison of pelvic incidence measurement using lateral x-ray, standard ct versus ct with 3d reconstruction. *Eur Spine J*. 2022; 31:241-247.
  20. IBM Corp. IBM SPSS Statistics for Windows, Version 26.0. Armonk, NY: IBM Corp; 2019. SPSS 26.0.
  21. Koo TK, Li MY. A guideline of selecting and reporting intraclass correlation coefficients for reliability research. *J Chiropr Med*. 2016;15:155-163.
  22. Hoy D, Bain C, Williams G, et al. A systematic review of the global prevalence of low back pain. *Arthritis Rheum*. 2012;64:2028-2037.
  23. Meucci RD, Fassa AG, Faria NM. Prevalence of chronic low back pain: systematic review. *Rev Saude Publica*. 2015;49:1.
  24. Vleeming A, Schuenke MD, Masi AT, Carreiro JE, Danneels L, Willard FH. The sacroiliac joint: an overview of its anatomy, function and potential clinical implications. *J Anat*. 2012;221:537-567.
  25. Wagner R, Haefner M. Uniportal endoscopic lumbar interbody fusion. *Neurospine*. 2020; 17(Suppl 1):S120-S128.
  26. Le Huec JC, Thompson W, Mohsinaly Y, Barrey C, Faundez A. Sagittal balance of the spine. *Eur Spine J*. 2019;28:1889-1905.

*Conflict of interest statement: The present publication was funded by Fundação Ciência e Tecnologia, IP national support through CHRC (UIDP/04923/2020). The remaining authors have no conflicts to report.*

*Received 14 February 2023; accepted 7 April 2023*

*Citation: World Neurosurg. (2023) 175:e809-e817.  
https://doi.org/10.1016/j.wneu.2023.04.026*

*Journal homepage: [www.journals.elsevier.com/world-neurosurgery](http://www.journals.elsevier.com/world-neurosurgery)*

*Available online: [www.sciencedirect.com](http://www.sciencedirect.com)*

*1878-8750/© 2023 The Author(s). Published by Elsevier Inc. This is an open access article under the CC BY-NC-ND license (<http://creativecommons.org/licenses/by-nc-nd/4.0/>).*